

International Society of Craniofacial Surgery

# ISCFS NEWSLETTER

Volume 1 | Number 2



## IN THIS ISSUE:

---

**NEW  
TECHNOLOGIES**

**WINDOW INTO  
HISTORY**

**HOW I DO IT:  
LATERAL  
CANTHOPEXY**

APRIL 2024

---

# MESSAGE FROM THE EDITOR

Thanks to all who contributed to the first edition of the ISCFS newsletter! There has been an overwhelmingly positive response and we are encouraged to see the flurry of dialogue among ISCFS members. After all, that is the purpose of the newsletter – to promote dialogue and engagement between biennial congresses. We hope you will learn something new along the way as well. Our column *How I Do It* features various ways members perform common procedures starting with, in this issue, lateral canthopexy. Please feel free to send suggestions for future *How I Do It* topics.

Thanks also to our members who tuned in to the inaugural ISCFS webinar, *Managing the Apert Midface* on April 22nd. Drs. Dunaway, Hopper, and Mathijssen presented compelling cases, prompting fiery discussion as experiences and points of view were shared. It is valuable to see that there are many paths to successful treatment of the Apert midface, one of the more challenging areas of our specialty.

As spring blooms in the northern hemisphere, there is an awakening of flora and fauna. Some of us with mild seasonal affective disorder feel a similar awakening of our creative juices. This can be a time of reflection as well as goal setting, and I encourage everyone to take a few moments to think about the role craniofacial surgery plays in your life. I am thankful for the science, the patients, our colleagues, and unsolved surgical challenges that make for a fulfilling life journey.



**JESSE TAYLOR**  
UNITED STATES

# TABLE OF CONTENTS

Message from the Editor Jesse Taylor	02
Message from the President Xiongzhen Mu	03
How I Do It: Lateral Canthopexy Christian El Amm Jonathan Britto Matthew E. Pontell	05
New Technologies Christian El Amm	14
Change to ICD-10 Diagnosis Codes for Craniosynostosis Michael Golinko	16
Confidence During Pterygomaxillary Dysjunction Shelby Nathan	17
Global Education Programs Primod Subash	19
Window Into History Riccardo F. Mazzola	21
Neurosurgery Corner Shailendra Magdum	23
Orthodontics Update Barry H. Grayson	26
Digitalizing the ISCFS Ben Massenburg	29
Event Calendar ISCFS	32

# MESSAGE FROM THE PRESIDENT

We have been busy planning an innovative, vibrant 2025 Congress in Shanghai!

We are so excited to highlight the wonderful work of our members against the backdrop of one of China's most beautiful cultural attractions. Importantly, the dates of the 21st ISCFS Congress have been changed to October 27-30, 2025. This decision was made after discussion and voting by the Council so that our members will have more time to schedule and avoid conflicts with other conferences.

The late October weather in Shanghai is cool and pleasant, and most cities nearby are also entering the best autumn scenery season.

I hope that everyone will enjoy a wonderful time in Shanghai.



**XIONGZHENG MU**  
ISCFS President  
CHINA

*"We have been busy planning an innovative, vibrant 2025 Congress in Shanghai!"*

---



INTERNATIONAL  
SOCIETY OF  
CRANIOFACIAL  
SURGERY

# ISCFS WEBINAR: ANTERIOR CRANIAL VAULT DISTRACTION FOR UNICORONAL CRANIOSYNOSTOSIS

JUNE 11, 2024 | 6 PM CET



## NEXT WEBINAR!

Join us on Tuesday, June 11, 2024, at 6:00pm CET for an in-depth discussion on **"ANTERIOR CRANIAL VAULT DISTRACTION FOR UNICORONAL CRANIOSYNOSTOSIS"** with panelists Jesse A. Taylor (United States), Lars Kölby (Sweden), Amanda Gosman (United States) and Jong Wo Choi (South Korea).

## ON-DEMAND

Our ISCFS Webinar on **"Managing the Apert Midface"** with panelists Drs. David Dunaway (United Kingdom), Irene Mathijssen (The Netherlands) and Richard Hopper (United States) will soon be available On-Demand.\*

\*On-demand recordings are only available to ISCFS Members and require a password for access.

# HOW I DO IT: LATERAL CANTHOPEXY




**CHRISTIAN EL AMM**  
UNITED STATES

## INTRODUCTION AND CLINICAL EVALUATION:

Craniofacial practitioners may perform a “lateral canthopexy” for a variety of clinical situations, and with varied intent. Clinical situations may include primary and secondary trauma, cosmetic facial rejuvenation, or correction of dysmorphology associated with craniofacial syndromes. The surgeon’s intent may include resuspension of a dehiscenced canthal insertion, or repositioning an ectopic lateral canthus. Under this framework, each scenario carries a different clinical evaluation and decision making.

Clinically, the lateral canthus is typically at or below the level of the medial canthus, creating a down sloping “antimongoloid slant” to the palpebral fissure, whereas a superolateral slant is desirable. The “lateral triangle” of the sclera may be smaller, and the eyelid position may be normal or in ectropion. The lower lid itself may be of normal length, or transversely elongated due to age-related changes or exophthalmos. Vertical deficiency is commonly observed in cicatricial ectropion and entropion. Alternatively, the eyelid may be structurally deficient both vertically and transversely in Tessier orbital clefts, Treacher-Collins Syndrome, Kabuki Syndrome, or others. When a structural deficiency exists, preliminary or concomitant replacement of the missing structures by palatal or eyelid mucosa, ear cartilage, and musculocutaneous flaps should be planned.



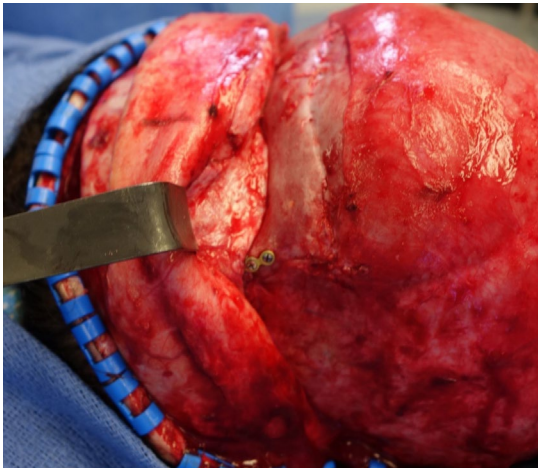


Figure 1: Patient undergoing hardware removal, midface suspension and lateral canthopexy after Fronto-Facial Advancement with distraction osteogenesis. The pericranium is incised 2 cm above the orbital rim and extensive subperiosteal dissection performed. Existing hardware exposed.

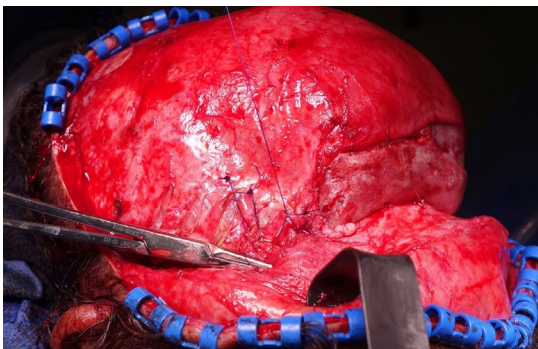


Figure 2: After removal of hardware, the soft tissues of the midface are elevated and suspended to the Temporalis Fascia.

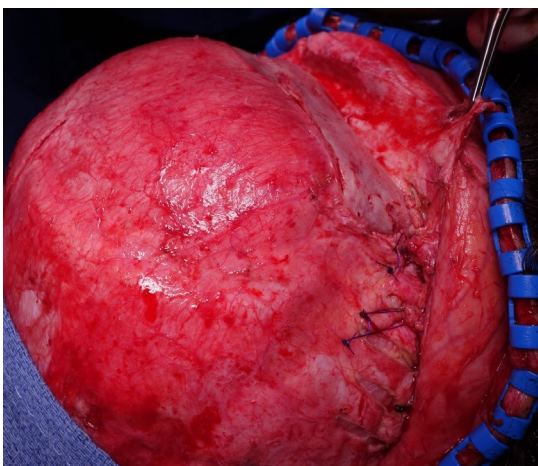


Figure 3: The periosteal flap is continuous with the Arcus Marginalis and mobility is tested clinically. Contouring the superior rim hooding facilitates mobilization of the complex.

The lateral canthus is the common lateral insertion of the superior and inferior tarso-ligamentous system and is continuous with the septum and deeper extensions through the lateral retinaculum. The tarsus is continuous with the orbital septum to the orbital rim, where a thick ligamentous system, the Arcus Marginalis, combines the attachment of the septum and Orbicularis Oculis to the periosteum. Contrary to common anatomical diagrams, the inferior eyelid septum does not travel directly to the orbital rim, instead taking a pronounced convex trajectory, following a projection caused by intra-orbital fat. This convexity can be easily seen on high-resolution CT scans (0.5mm voxels). The trajectory is longer in proptotic globes, and shorter in deep-set eyes. As such, the attachment of the tarsus to the orbital rim is not the main restriction on movement of the lateral canthus.

The main restriction on its movement is the continuity of the canthal system with the Lockwood and Whitnall ligaments, enveloping the globe. The globe is enclosed in the osseous orbit, with the superior rectus and minimal fat between the globe and the orbital roof. Thus, repositioning the lateral canthus superiorly is likely to fail without ancillary procedures. Such ancillary procedures include

“at least 180 degrees” of dissection circumferentially, as advocated by Tessier, and burring modification of the inclination of the superior and superolateral orbital rim. Assessment of coronal and sagittal CT scan cuts informs on the distance between globe and roof, as well as the position of the globe at its maximum diameter relative to the rims.

Proptotic globes have “stretched” lower lids, and less interference by the superior orbital rim, allowing for an easier superior repositioning of the lateral canthus. Wide subperiosteal undermining of the perio-orbita and burring of the superolateral orbital rim “hooding”, enables a superior vector of displacement of the lateral canthus, and is helpful in minimizing the syndromic stigmata of Crouzon’s and Treacher Collins Syndrome. Support of the inferior orbital rim and floor is needed in the latter case. In deep-set globes, it is extremely difficult to manipulate the position of the lateral canthus in isolation, instead requiring periobital osteotomies, box osteotomies, or facial bipartition.

Attention should be placed on tension of the repair. For example, lateral canthopexy concomitant with a medial canthopexy should be done with minimal to no tension, otherwise it is best done in a deferred fashion. In

our practice, after major midfacial osteotomies, a lateral canthopexy is often performed in the setting of a planned second stage procedure, combined with hardware removal, bone contouring, midface suspension, and fat transfer (**Figure 2**). In general, a “hard-stop” is felt at the correct location, some tension is desirable, and over-tensioning is counterproductive.

**LATERAL RETINACULAR SUSPENSION:**

A 1 cm incision is made in the lateral extent of the superior tarsal crease, extending over the lateral orbital rim. A small amount of blunt dissection is carried inferiorly over the lateral canthal system to avoid skin bunching. A 2mm counter-incision is made over the lower lid 4mm below the canthus. A 4-0 tapered point needle with permanent braided material is passed from the upper lid incision deep to the bulk of the canthal tendon and extruded through the lower lid counter-incision, then passed back from the counter-incision, superficial to the bulk of the lateral canthal tendon, and exited through the upper eyelid incision.

The suspension suture can then be secured over the orbital rim to the periosteum or temporalis fascia insertion, in a supero-lateral vector. This extra-orbital suspension is a fast and expedient way to suspend the canthal structures in elderly patients, in patients

with narrow lateral scleral triangles, and in patients that do not have deep-set eyes. Judicious superolateral adjustment of the vector prior to securing the suture is often needed. Suspension of the retinaculum favors the lower lid structures, and a vector that is too superior may “de-tension” the upper lid structures, resulting in a small amount of temporal eyelid ptosis, or an exaggerated S-curve to the upper eyelid free margin. A vector too lateral may result in loss of apposition of the lateral eyelid to the globe, with pooling of tears (“plerolacrima”), and an appearance similar to Euryblepharon.

In patients with deep-set eyes, or if these undesirable secondary deformities are observed, suspension of the lateral retinaculum is secured intra-orbitally, to the lateral orbital wall. In this case, the vector is mainly posterior. If the lateral wall periosteum is not detached, a plane is created supra-periosteally, and the retinacular suspension suture is secured slightly posterior and superior to Whitnall’s tubercle. In most craniofacial procedures, the lateral wall periosteum is detached, and the suspension suture is secured to bone, using common bone-anchoring methods. We prefer to tie the suture around a 4 or 5 mm osteosynthesis screw, then anchor it to the lateral wall. Alternatively, two holes can

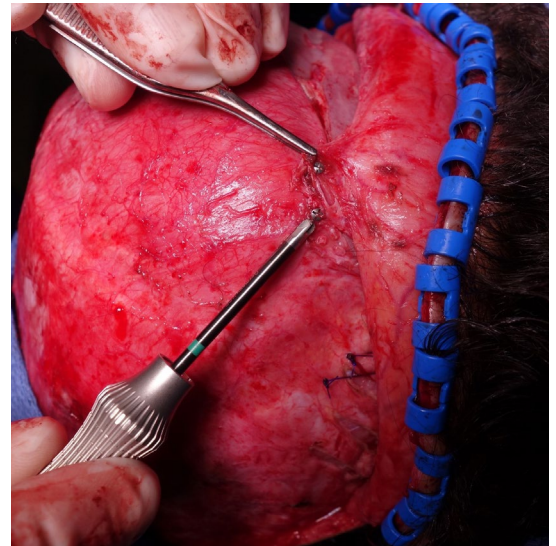


Figure 4: The flap is elevated and suspended to bone. Use of mono-cortical screws facilitates secure re-attachment. Here we advanced the flaps 6mm until a “hard-stop” is felt.

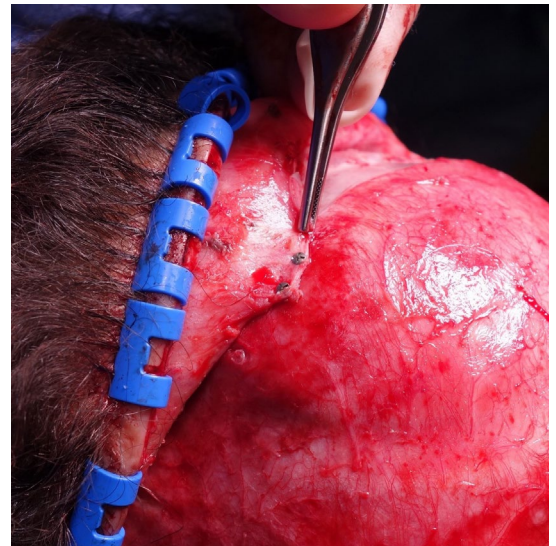


Figure 5: Contralateral suspension, 8 mm in this case. The amount of advancement is tailored to optimize symmetry.

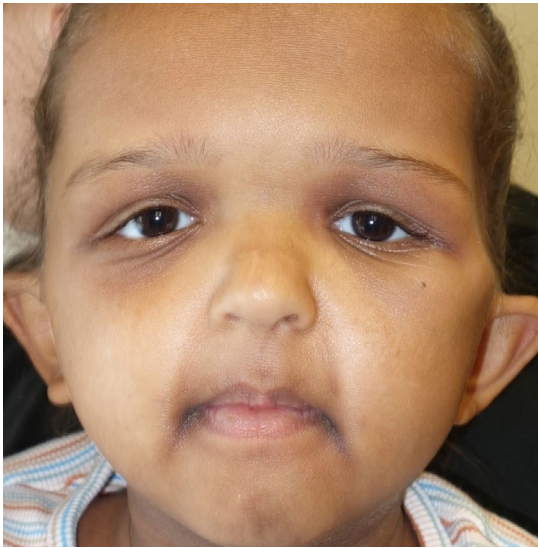


Figure 6: Pre-operative frontal view of patient with Crouzon with Acanthosis Nigricans after completion of Fronto-Facial Advancement, showing down-sloping, "anti-mongoloid" palpebral fissures. Note distraction hardware visible over the lateral zygoma.

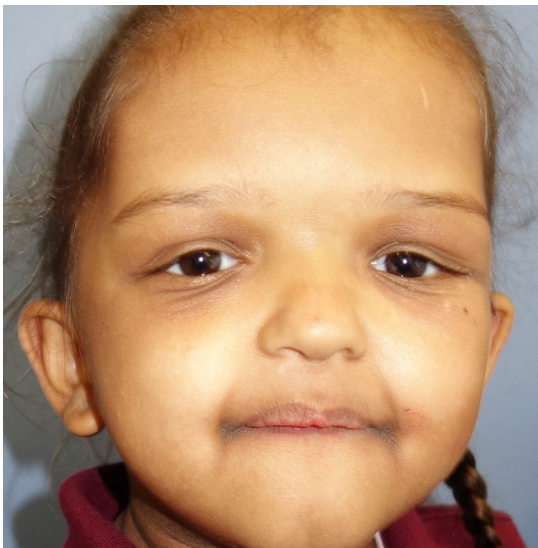

Figure 7: After hardware removal, midface and Arcus Marginalis suspension lateral canthopexy. No fat grafting was done in this young patient. Note improvement of several syndromic stigmata. A lateral retinacular suspension was combined on the left. Note slight temporal ptosis of the left upper lid, with "exaggerated S-curve" of the lash line due to the vertical vector chosen.

be made in the lateral orbital wall and the suture passed through each and suspended externally. Excessive tension can result in globe irritation due to increased friction, and loss of apposition of the lower lid punctum to the lacrimal pool medially ("punctal apposition syndrome").

**ARCUS MARGINALIS SUSPENSION:**

The technique utilizes a coronal approach. The periorbital pericranium is incised 1-2 cm above the orbital rim and dissection proceeds in a subperiosteal plane for an extensive, near circumferential dissection of the periorbita (**Figure 1**). If superior orbital rim hooding is present, it is contoured to maintain an upward slope of the roof and rim. This allows the globe to translate anteriorly when vertical traction is placed on Lockwood's ligament. Augmentation of the orbital floor and inferior rim is often needed, in cases where a deficiency exists, such as commonly seen with Treacher Collins, or post midface advancement, where floor osteotomies have not fully ossified. Vertical traction on the orbital bandeau periosteum elevates the entire capsulo-palpebral system, canthus, as well as the tarsal and septal system. The incised periosteum is advanced, overlapping the cut edge and secured to bone (**Figures 3-7**).

In certain situations, such as correction of severe exorbitism, the Lateral Retinacular system and tarsal plates are elongated, and a Lateral Retinacular Suspension can be combined. The tarsus adapts fairly quickly to the position of the globe, and it is rare to need tarsal shortening. If needed, a conservative tarsal strip is effective.

Elevation of the lateral canthal position is often temporary with lateral retinacular suspension, whereas 2-3 mm of permanent elevation can be obtained with Arcus Marginalis suspension.

*"Attention should be placed on tension of the repair."*



# CANTHOPEXY – WHAT, WHY, WHEN, HOW? A PERSONAL PERSPECTIVE

*"Well-judged canthal support surgery will meet a patient's aesthetic request..."*



**JONATHAN BRITTO**  
UNITED KINGDOM

## WHAT?

Canthopexy, (referring to lateral canthopexy), is a surgical strategy that serves the patient beautifully for success in eyelid appearance, function, and emotion. Similarly, a badly done canthopexy will compromise these outcomes. The aims, indications, alternatives, and expectations of outcome of this family of procedures, which includes sophisticated techniques of canthoplasty, therefore merit thought - particularly as there are myriad published surgical techniques across many allied professional specialties.

## WHY?

Technically proficient lateral canthal support surgery (canthopexy or canthoplasty) will provide functional comfort by stabilizing the lower eyelid margin against the tilt malposition of ectropion or entropion, approximating the puncta to facilitate tear drainage, and preventing an oculopalpebral diastasis in optimising the relationship between the palpebral and bulbar conjunctivae.

Well-judged canthal support surgery will meet a patient's aesthetic request to elevate the

lateral canthus and change the shape of the lateral third of the lower eyelid margin, and to create a sharp corner where the upper and lower eyelid margins and grey-line meet. This is an important aesthetic unit of the face, scrutinised in photography and in the make-up mirror. Such successes in appearance change bring powerful emotional benefit to patients, evidenced in QPROM outcomes from aesthetic eyelid surgery.

## WHEN?

Whereas the tone, tension, and shape of the lower eyelid margin are influenced by canthal support surgery, it is a misconception that canthopexy alone will support the lower eyelid. Canthopexy stabilises and shapes the eyelid margin in the otherwise well supported eyelid.

Additional surgical strategies such as orbicularis flaps (with retaining ligament release), midface lift, and the correction of a skeletal negative vector may be necessary to provide lower eyelid support in aesthetic and reconstructive craniofacial surgery and may be indicated independently of the decision to stabilise the eyelid margin. **(Figures 1.1, 1.2, 1.3).**

Similarly, over-tensioned and malpositioned canthal support surgery (particularly those techniques that remove tissue) may create problems such as diastasis and epiphora which they were intended to mitigate. A particular judgement is the distance between the soft tissue lateral canthus and the inner aspect of the orbital periosteum at the level of Whitnall's tubercle - over tensioning the lateral canthopexy will create a diastasis that is difficult to resolve.

Consider various scenarios in: surgical support to the paralysed eyelid, aesthetic blepharoplasty, and restorative midface surgery in congenital craniofacial syndromes. The negative vector of the Crouzon/Apert face is an extreme example of poor eyelid support. Unless midface position is corrected, eyelid support will be poor and canthopexy alone will bowstring the lower eyelid. In the paralytic lower eyelid, an orbicularis flap will assist by lower lid support to a canthoplasty (**Figure 2**) which stabilises the position of the eyelid margin. In the over-resected aesthetic blepharoplasty, canthopexy will not mitigate the requirement to recruit or replace skin into the lower eyelid. (**Figure 1.2**).

**HOW?**

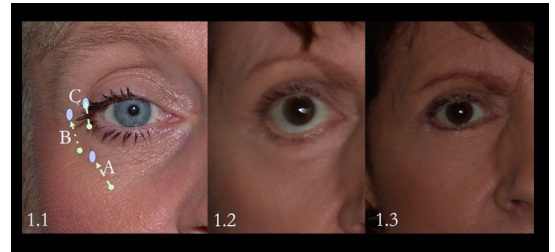
A detailed review of technical alternatives in canthal support surgery is not indicated here.

However, there are some principles that serve well in oculoplastic reconstruction for the paralysed eyelid, tumour surgery, craniofacial surgery, and aesthetic blepharoplasty.

1. The orbit is a "coat-hanger" for the face, and specific locations on the lateral/inferolateral orbital margin provide stable, secure, accurate and reliable proximal fixation for the cheek (SOOF and subperiosteal midface flaps), lower eyelid (orbicularis flaps), and eyelid margin (canthopexy/canthoplasty) with the opportunity for buried knots and short spanning suture lengths. (**Figure 1.1**)

2. The principle of building progressive lower eyelid and eyelid margin support from the cheek up progressively takes the tension away from the lower eyelid margin such that the canthopexy becomes a non-tensioned margin-stabilising technique. Restored canthal and lower eyelid position in frontofacial advancement may benefit from all of these techniques, whereas aesthetic lower lid blepharoplasty might require simply orbicularis flaps (all other lower eyelid supports being intact) and no canthal support at all.

3. Vertical or superomedial elevation of the cheek benefits aesthetics and takes tension out of



Figures 1.1, 1.2, 1.3 - 1.1: Position of distal-to-proximal fixation of soft tissues in the cheek (A), orbicularis muscle (B), and lateral canthus (C). Proximal fixation at (A) is a cuff of SOOF/periosteum at the inferolateral orbital margin; at (B) is the lateral orbital margin periosteum at the level of the orbicularis raphe; and at (C) is the inner orbital periosteum at or above the level of Whitnall's tubercle. 1.2: lower eyelid malposition from over-resected aesthetic lower blepharoplasty. 1.3: corrected eyelid position using composite midface and orbicularis lifts with lateral canthopexy.

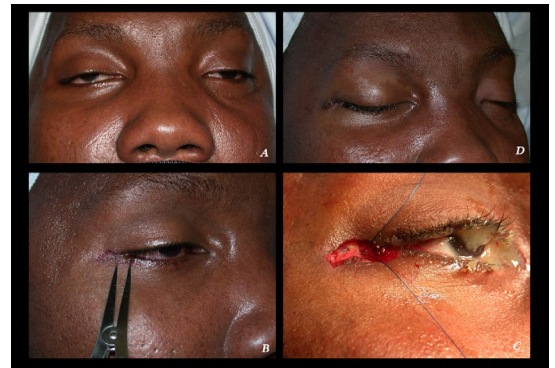

Figure 2 - Counter-clockwise: Lateral tarsal strip canthoplasty in paralysed right lower eyelid with lateral epiphora. (A) Right lower eyelid malposition with scleral show. (B) 4 mm tarsal strip planned. (C) proximal fixation with drill hole at level of Whitnall's tubercle directing to inner orbit. (D) elevated, shaped, lower eyelid relieves epiphora.

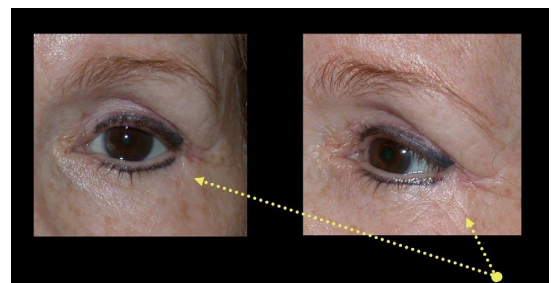


Figure 3 - Over tensioned lateral canthopexy creates "pleat" in lower eyelid which crosses dynamic smile lines.

the lower eyelid. The subperiosteal cheek lift is fixed at the periosteum of the outer aspect of the inferolateral orbit. **(Figure 1.1)**. The correct vector in the cheek and orbicularis resuspension is important to ensure that the dynamic smile lines in the lower eyelid run across the lid and inferolaterally. An over tensioned canthopexy in a superolateral direction is stigmatising, as it will create a vertical or inferomedial tension line crease across the eyelid which is directly counter to natural dynamic lines of smile. **(Figure 3)**.

4. Supported appropriately from below, the de-tensioned lower eyelid might benefit from horizontal shortening of the eyelid margin by means of a canthoplasty (such as a lateral tarsal strip or a modified wedge resection) to approximate and stabilise the lower eyelid margin correctly. **(Figure 2 - Vertical support and horizontal shortening.)** The anterior lamellar of the lower eyelid, suitably trimmed for inset is supported and shaped by an orbicularis muscle flap to provide a gentle sub-tarsal sulcus and orbicularis support to the lower eyelid (having released the orbicularis retaining ligament). This is fixed to the periosteum of the outer aspect of the lateral orbit, at or above the level of the orbicularis raphe **(Figure 4.1)**.

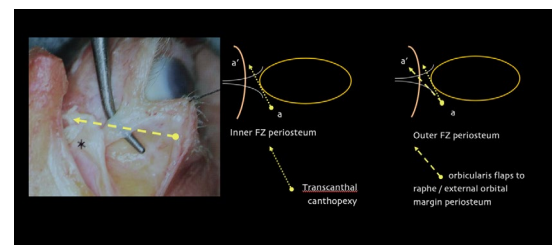
5. The eyelid margin, the tension having been relieved by support from below (cheek/orbicularis flap as necessary) is stabilised into the inner aspect of the orbital periosteum at the level of Whitnall's tubercle (emulating the trajectory and fixation of the inferior crus of the lateral canthal tendon). The simplest form of this is a trans-canthal canthopexy, via an upper eyelid crease incision passing a suture from inner orbital periosteum through the lateral retinaculum/ tarsal plate of the lower eyelid, through the pre-tarsal orbicularis and back through all the layers of the lid. **(Figure 4.2)**. The knot is buried, the spanning suture is short, and the eyelid margin is stabilised, apposing bulbar and palpebral conjunctiva with no gap. With just the right amount of tension in the orbicularis and the skin flap, the dynamic smile lines will run in a natural direction.

More sophisticated strategies which might shorten a lax lower eyelid margin include tarsal strips; however, the principals are the same: to approximate the grey line if disrupted, to shape the inferolateral eyelid margin, to stabilise the lower eyelid and anterior eyelash projection, to avoid inferior punctal malposition. The coronal position of the lateral canthus relative to the medial canthus should be sympathetic to

appearance, function, and emotion, and not create a diastasis gap between the canthus and the bulbar conjunctiva. Where the canthal angle has been incised/ disrupted, the aim is to restore apposition of the grey-line and a sharp restored angle.

**SUMMARY**

The number and variety of our patients for whom lateral canthal support surgery will be of benefit is matched by the number and variety of techniques to achieve it. There is no ideal technique, but there are reasonable principles. Craniofacial surgeons dealing with facial restoration for appearance, function, and emotion are well placed to consider these principles in the service of our patients with craniofacial developmental difference, oculoplastic reconstructive requirements, facial paralysis, and those seeking aesthetic change for confidence in appearance.



Figures 4.1 and 4.2 - Schema shows requirement to fix orbicularis flaps to the external orbital periosteum at the orbicularis raphe, contrasting with the fixation of the lateral retinaculum/lateral tarsal plate via the inferior crus of the lateral canthal tendon to the internal periosteum of the orbital margin. Fixation of the canthopexy too laterally or too tightly will result in an oculopalpebral diastasis with functional and aesthetic consequences.

# HOW I DO IT: LATERAL CANTHOPEXY

*"Subperiosteal dissection can proceed all the way down the lateral orbit and across the inferior orbital rim, if needed."*



**MATTHEW E. PONTELL**  
UNITED STATES

I follow the procedure described by Scott P. Bartlett, MD from the Children's Hospital of Philadelphia. The patient is prepped and draped in the standard fashion and the eye is irrigated with balanced salt solution prior to placing a scleral shield. Local anesthetic with epinephrine is infiltrated in the supra-periosteal plane along the lateral orbital rim.

A 10mm upper blepharoplasty incision is marked within the relaxed skin tension lines, over the lateral orbital rim in the area of the "crow's feet." The incision is opened with a scalpel and deepened with electrocautery until the subperiosteal plane is reached. Subperiosteal dissection proceeds both cranially and caudally along the anterior surface of the lateral orbital rim with a periosteal elevator. The lateral periorbital is then dissected off the inside of the lateral orbital wall. Subperiosteal dissection at this level proceeds cranially to expose the fronto-zygomatic suture, which can be used as a reference point for symmetry. Subperiosteal dissection then proceeds caudally, releasing the existing lateral canthal

attachments. Subperiosteal dissection can proceed all the way down the lateral orbit and across the inferior orbital rim, if needed. This can become useful in cases with severe cicatricial disfigurement or in cases of congenital lateral facial clefts, such as the Tessier 6 cleft commonly seen in patients with Treacher Collins-Franceschetti Syndrome.

After the subperiosteal dissection is complete, the freed lateral canthal ligament is grasped and translocated into the desired position. If the canthal ligament does not translocate freely, further subperiosteal dissection should proceed. In cases with severe distortion of lateral canthal position, such as Nager syndrome or Treacher-Collins Franceschetti Syndrome, superior translocation may be limited by an inadequacy of lower eyelid skin. Despite extensive subperiosteal dissection, the lack of lower eyelid skin may be prohibitive. In cases such as these, the lower eyelid skin and muscle can be transected to allow for maximal canthal elevation. The lower eyelid deficit is then reconstructed with a

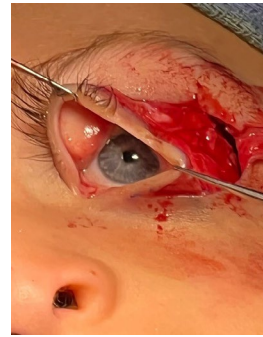myocutaneous lid-switch flap, harvested from the upper eyelid.

Once the lateral canthus has been mobilized to its desired position, two holes are drilled through the lateral orbital rim with a 1.5mm wire-pass bur. At this point the fronto-zygomatic suture is used as a reference point to allow for symmetry.

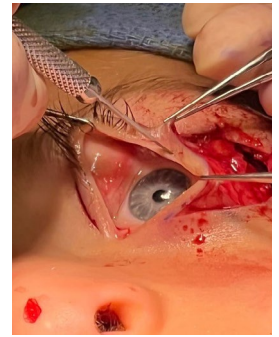
An additional injection is performed in the lateral canthal angle of the conjunctiva. One single-pronged skin hook is placed in the conjunctiva just cranial to the lateral canthus and one is placed in the conjunctiva just caudal to the lateral canthus. With elevation of the gray line of the lateral cantal angle is brought into view and leveled (**Figure 1**). Using a 6700 Beaver Mini-blade, a 5mm incision is made directly on top of and through the gray line (**Figure 2**). A 3-0 suture, either Mersilene or Ethibond, is selected. The suture needle is removed, and each free end of the suture is passed through an eyelet of a free Keith needle. Each Keith needle is inserted through the canthal incision (**Figure 3**). The needle trajectory is parallel, but several millimeters apart so that the lateral canthal tendon can be ligated (**Figure 4,5**). Through the blepharoplasty incision, the free ends of each suture are grasped and retracted to ensure that the lateral canthal tendon has been successfully captured. Each free suture

end is threaded through a separate hole in the lateral orbital rim (**Figure 6**). The two ends are tied together just tight enough to seat the lateral canthus in the desired position.

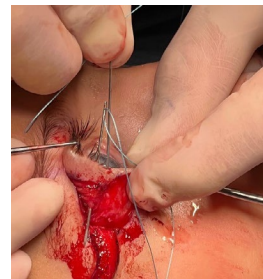The gray line incision can be closed with a 6-0 fast absorbing suture and the blepharoplasty incision is closed using fine, monofilament absorbable suture.



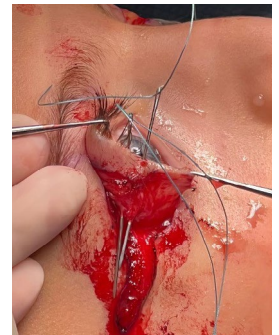
*Figure 1. Image demonstrates elevation of the lateral canthal margin by two single-pronged skin hooks. This maneuver exposes and straightens the gray line. Note the large lateral access incision. This patient was undergoing a concomitant myocutaneous lid-switch flap for lower eyelid tissue deficiency.*



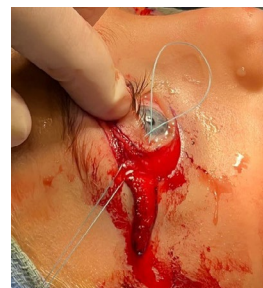*Figure 2. Using a 6700 Beaver mini-blade, an incision is made directly in the exposed lateral canthal gray line.*



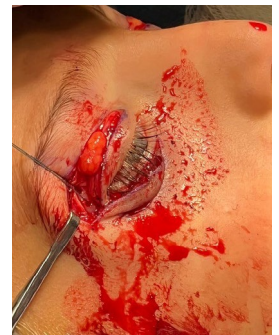
*Figure 3. Each free end of a 3-0 Mersilene suture is passed through the eyelet of a free Keith needle which is inserted through the conjunctival incision and passed into the blepharoplasty incision.*



*Figure 4. Note the trajectory of the Keith needles, they are parallel but spaced several millimeters apart in order to ligate the lateral canthal tendon.*



*Figure 5. Note the lasso created using this maneuver. This is used to capture the lateral canthal tendon for repositioning.*



*Figure 6. Each free end of the 3-0 Mersilene suture is seen being brought through a separate drill hole in the lateral orbital rim.*

# NEW TECHNOLOGIES

*"Accurate overlay of the virtual models is now approaching the millimeter accuracy of traditional surgical navigation."*



**CHRISTIAN EL AMM**  
UNITED STATES

## PREOPERATIVE MARKING GETS A TECHNOLOGICAL BOOST

Augmented Reality Navigation (ARN) is adding a technological spin on the age-old habit plastic surgeons have of detailed pre-operative marking. Instead of elaborate drawings of vessels, perforators, bone cuts and skin paddles, the surgeon issues voice commands and waves their finger in the air.

Made possible by optical see-through devices, these spatial computing devices constantly track the environment to overlay relevant anatomy extracted from preoperative imaging or Virtual Surgical Planning (VSP) onto the surgeon's visual field.

Visualization in the immediate vicinity of the patient offers the "many screens" benefit, especially when the 3D models are projected with the same perspective as the surgeon sees the patient. While 3D reconstructions are commonplace today, they are shown on a screen from

specified angles. When 3D models are visualized in the surgical perspective, less cognitive load is needed for "field transfer" of preoperative imaging to the surgical field.

Accurate overlay of the virtual models is now approaching the millimeter accuracy of traditional surgical navigation. Visualization in overlay increases confidence performing surgical tasks that rely on haptic feedback, such as pterygomaxillary disjunction, closed reduction of subcondylar fractures, reduction of a zygoma in 6 Degrees of Freedom (6DOF), as well as common tasks such as rhinoplasty osteotomies.

Virtual cutting guides, reduction guides and registration guides are available instantaneously, and are infinitely adjustable. Using them, however, requires a significant adjustment, akin to getting used to surgical loupes.

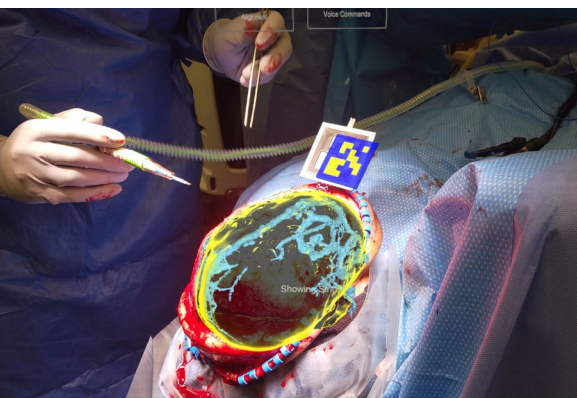


Figure 1: Visualizing dural sinuses and dural surfaces prior to low occipital craniotomy may be helpful in cranial vault remodeling.

While the perception of depth is generated by stereoscopic vergence differences, the virtual models are projected either at infinity, or at two meters in many current systems. This "Vergence-Accommodation Conflict" between virtual models projected at two meters, and the surgical field at 0.45 meters will be with us until "light field" holographic technologies are adopted.

Video see-through systems, in contrast, are opaque devices that rely on a video feed for "co-visualization," merging the virtual and the real. While convincing enough for some folks to don these devices and walk into oncoming traffic, the video systems do not have the dynamic range of the human eye, and suffer perspective distortion in the near field, where surgery is commonly performed.

These "Medical Extended Reality" (c.f. FDA) systems promise cost savings on colored surgical markers, 3D printed cutting guides, 3D printed models, the robot invasion, as well as efficiency and safety gains in the operating room. For five years now, our experience confirms that, as well as cross-specialty experience in general surgery, ENT, orthopedics and neurosurgery.

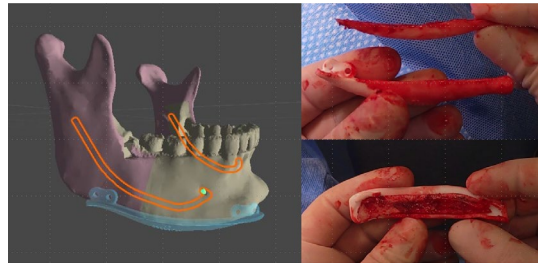


Figure 2: Virtual registration guides simplify tracking of multiple segments, are adjustable, and provide shape information for contouring in addition to linear movements and rotational adjustments.




Figure 3: Virtual cutting guides in locations where bulky 3D printed guides require additional dissection or excessive traction on sensitive structures.

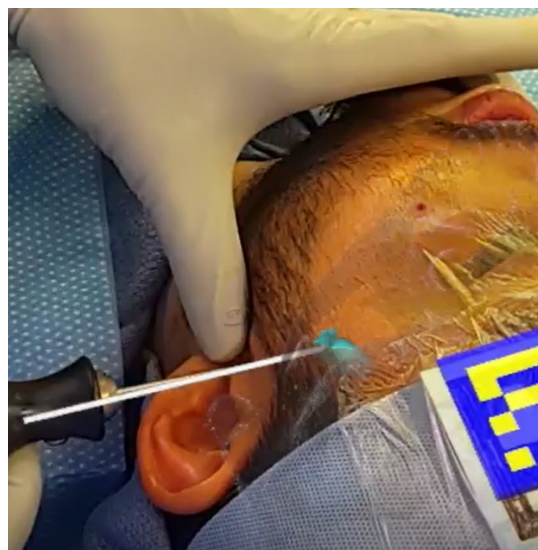


Figure 4: Closed reduction of subcondylar fracture under Augmented Reality Navigation.

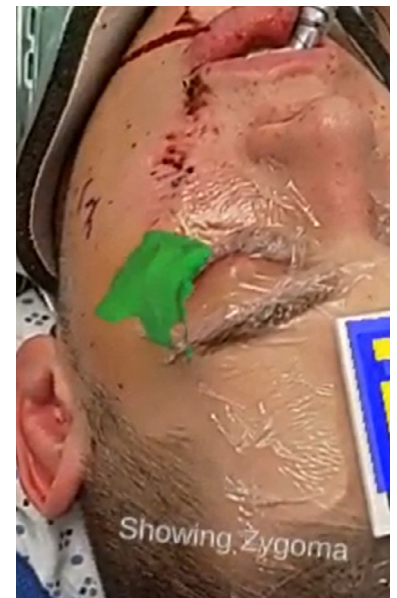
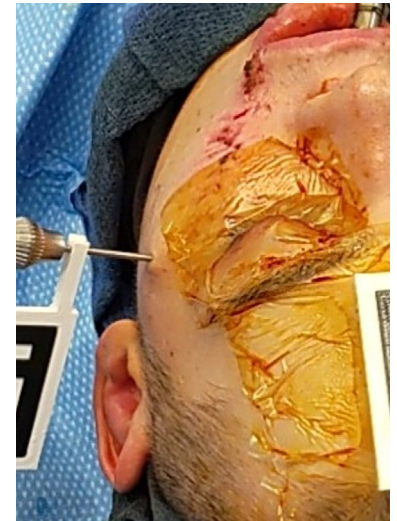
Figure 5: Tracking zygoma position in 6-DOF degrees-of-freedom.

Disclosure: An ISCFS Active member since 2013, Christian El Amm, is the founder of Xironetic and a practicing pediatric plastic surgeon.

# NEW ICD-10 DIAGNOSIS CODES TO IMPROVE CRANIOSYNOSTOSIS CLASSIFICATION

*"... 2023 saw one of the most significant improvements.."*



**MICHAEL GOLINKO**  
UNITED STATES

October of 2023 saw one of the most significant improvements to the ICD-10 code for craniosynostosis, Q75.0.

Nearly four years after members of the American Society of Pediatric Neurosurgeons (ASPN), the American Society of Craniofacial Surgeons (ASCFS), and the American Academy of Pediatrics (AAP) requested a revision of the craniosynostosis

ICD-10-CM diagnosis code (Q75.0) to provide more clinical granularity, a multi-institutional working group of pediatric neurosurgeons, plastic surgeons, and pediatricians from Vanderbilt University Medical Center and Boston Children's Hospital were assembled to revise Q75.0.

The working group solicited mentorship from international authorities on the ICD system, including members of the AAP Committee on Coding and Nomenclature and the Centers for Disease and Control's (CDC) ICD-10 Coordination and Maintenance Committee (CDC-CMC). Together, the working group revised the Q75.0 code to include the necessary clinical granularity, including the type of craniosynostosis (i.e., sagittal, coronal, metopic, lambdoid, other, and not specified), laterality (i.e., unilateral, bilateral, not specified), and number of sutures (i.e., single, multiple).

The new codes, that are now active globally across all systems, are summarized

here. A published report is freely available in **PubMed Central® (PMC)**: [New ICD-10 Diagnosis Codes to Improve Craniosynostosis Classification \(nih.gov\)](#).

Summary of ICD Diagnosis Code Revision for CS (Q75.0)
Q75.00 CS unspecified
Q75.001 CS unspecified, unilateral Q75.002 CS unspecified, bilateral Q75.009 CS unspecified
Q75.01 sagittal CS
Q75.02 coronal CS
Q75.021 coronal CS, unilateral Q75.022 coronal CS, bilateral Q75.029 coronal CS, unspecified
Q75.03 metopic CS
Q75.04 lambdoid CS
Q75.041 lambdoid CS, unilateral Q75.042 lambdoid CS, bilateral Q75.049 lambdoid CS, unspecified
Q75.05 multisuture CS
Q75.051 cloverleaf skull (includes Kleeblattschaedel skull) Q75.052 pansynostosis Q75.058 other multisuture CS Excludes: coronal CS, bilateral (Q75.022) Excludes: lambdoid CS, bilateral (Q75.042)
Q75.08 other single-suture CS



# CONFIDENCE DURING PTERYGOMAXILLARY DYSJUNCTION

*"The purpose of our current study is to further understand surgeons' preferences and confidence while performing PM dysjunction."*



**SHELBY NATHAN**  
UNITED STATES

This article is related to a survey recently circulated to all ISCFS Newsletter readers.

Pterygomaxillary (PM) dysjunction is a maneuver commonly used for midface craniofacial reconstruction, which involves separation of the maxillary bone and pterygoid plates. Various techniques, instruments and outcomes have been described, given the anatomic location and blind nature of the procedure. This can occasionally lead to discrepancies in final osteotomy positions, which may in turn result in altered clinical outcomes. The purpose of our current study is to further understand surgeons' preferences and confidence while performing PM dysjunction. Below is a summary of the preliminary data collected from survey responses from surgeons around the world. By collating a broad base of experiences, we hope this data may further the education surrounding this procedure and ultimately enhance surgical outcomes.

The initial survey was distributed in March of 2024 and since then, there have been a total

of 93 respondents. Much of the survey group (70%) are plastic surgery trained and represent seven international geographic regions; North America (49%), Asia (19%), European Union (18%), South America (7%), United Kingdom (4%), India (2%) and Australia (1%). Eighty-eight percent of respondents currently serve in an attending or faculty position and are in various stages of their career. Thirty-one percent have greater than 20 years of experience, 25% noted 0-5 years of experience and 21% have been in practice for 6-10 years. When queried on the number of craniofacial procedures (including cranium, facial bone, or cleft reconstruction), 75% reported performing >50 of said cases per year. Midface, or specifically fronto-orbital advancement procedures for craniosynostosis, were fewer in number (46% and 35% reported doing 0-5 and 5-10 per year, respectively).

With regards to intraoperative technique, it is common for surgeons to utilize one or both of the following approaches: "top-down" via bicoronal incision or "bottom-up" through an intraoral incision. In this

sampling of surgeons, 54% of respondents used both a "top-down" and "bottom-up approach", whereas 37% and 9% reported using *only* bottom-up and top-down approaches, respectively. Perioperative adjuncts, such as virtual surgical planning (VSP), intraoperative navigation and stereolithographic models were largely used in combination, with VSP being the most common tool used in isolation and in combination. Its use was reported by 77% of the cohort.

We hope to continue gathering responses to potentiate the results of this study and understand surgeons' practice models and confidence with pterygomaxillary dysjunction. Thank you to those who have contributed to this work already and to those of you able to add their responses to our survey at this time.

Thank you to those who have contributed to this work already. To those of you able to add responses to our survey at this time, [CLICK HERE](#).

*"Pterygomaxillary (PM) dysjunction is a maneuver commonly used for midface craniofacial reconstruction, which involves separation of the maxillary bone and pterygoid plates."*

---

# ISCFS NEWSLETTER

Volume 1 | Number 3

## HOW I DO IT: Management of Unicoronal Craniosynostosis

To submit an article of 750-1000 words with images as needed, send it to [admin@iscfs.org](mailto:admin@iscfs.org) no later than Saturday, June 15.



JULY 2024

# GLOBAL EDUCATION PROGRAMS

*"A significant outcome of the meeting was the proposal to establish a task force dedicated to unifying all caregivers involved in managing craniofacial anomalies in India."*



**PRIMOD SUBASH**  
INDIA

## THE AMRITA CRANIOFACIAL UPDATE

The Fourth Amrita Craniofacial Update was held over two days at the Amrita Institute of Medical Sciences in Kochi, India on January 27-28, 2024. In association with the Indian Society for Cleft Lip, Palate and Craniofacial Anomalies (ISCLPCA), the Indian Society for Pediatric Neurosurgery (INDSPN), and the International Society of Craniofacial Surgery (ISCFS), this event brought together experts and professionals from around the globe to delve into the complexities of craniofacial surgery.

Organized by the Pediatric Craniofacial Surgery unit, spearheaded by Suhas Udayakumar and me, the program was structured around discussions and short lectures covering a wide array of topics. From perioperative care to minimally invasive surgery, and from midface procedures in very

young children to craniofacial trauma and hypertelorism, the agenda encompassed vital aspects of craniofacial surgery.

The conference served as a platform for craniofacial surgery teams from various regions of the country to converge and exchange insights. With participation from 35 countries, the hybrid conference format enabled fruitful deliberations among international experts and attendees. Distinguished faculty members from leading institutions within the country, as well as renowned craniofacial surgeons from across the world, including Steven Wall, Shailendra Magdum, Moorthy Halsnad, and Jagajeevan Jagadeesan in the UK, enriched the discussions with their expertise and experiences.

A significant outcome of the meeting was the proposal to establish a task force dedicated

*"The conference served as a platform for craniofacial surgery teams from various regions of the country to converge and exchange insights."*

---

to unifying all caregivers involved in managing craniofacial anomalies in India. This initiative aims to consolidate the efforts of various professionals under the umbrella of the Indian Society of Cleft Lip Palate and Craniofacial Anomalies. Given the absence of a specific body for craniofacial surgery in India, the task force represents a crucial step towards fostering interdisciplinary collaboration and promoting comprehensive

patient care. By bringing together professionals from diverse disciplines, including neurosurgeons, plastic surgeons, and maxillofacial surgeons, the task force seeks to create a platform for shared expertise and collective action. This collaborative effort reflects a steadfast commitment to advancing the standards of patient care and enhancing interdisciplinary cooperation within the field of craniofacial surgery.



# WINDOW INTO HISTORY

## CRANIOSYNOSTOSIS: THE FIRST ILLUSTRATIONS IN MEDICAL LITERATURE

### FOREWORD

In 1632, Giovanni Battista Cortesi published four illustrations of the deformities of the cranial vault, caused by premature synostosis.

**Giovanni Battista Cortesi** (1554-1636) (**Figure 1**) was born in Bologna and studied medicine at Bologna University under Giulio Cesare Aranzio (1530-1589) and Gaspare Tagliacozzi (1545-1599), learning the techniques for nasal reconstruction. In 1583, he graduated in medicine, and soon became Lecturer of Anatomy and Surgery at Bologna. He maintained this position until 1599 when he moved to Messina. Cortesi was a follower and disciple of Tagliacozzi - and the only one who performed the arm flap operation after Tagliacozzi's death. In 1599, on his way to Messina, he stopped in Tropea to pay a visit to the brothers Pietro and Paolo Viano, known for their art of nasal repair using the arm flap procedure, with the aim of learning details of the technique directly from them. To his great surprise, he didn't meet anyone. After the deaths of Pietro and Paolo that had occurred sometime

before Cortesi's visit, the clinic that had been very busy in the past, was nearly abandoned. Instead, he could only see their instruments about which he wrote: they seemed crude to me. He remained at the newly established Messina University, where he was appointed Professor of Surgery, for twenty-one years [1].

During the period 1619-1635, Cortesi published numerous works including *Miscellaneorum Medicinalium Decades Denae* (*Miscellany of Medicines, divided into ten decades*) [2], where he describes the procedures for nasal repair, lip reconstruction, either for cleft or post-traumatic purposes, and restoration of the auricle using the arm flap procedure, and *De vulneribus capitis* (*On head wounds*) [3]. He became very famous, treated important personalities, and was appointed chief physician to the Pope and protophysician in Rome. In 1620, Bologna University offered him a position which he declined. He died in Reggio Calabria (southern Italy) in 1634, aged 80.



**RICCARDO F. MAZZOLA**

History Editor  
ITALY

*"During the period 1619-1635, Cortesi published numerous works..."*



Figure 1 - Engraved portrait of G. B. Cortesi (1554-1636). From: *Miscellaneorum Medicinalium decades denae*. Messina, Pietro Brea, 1625.




Figure 2 - Title page of *Tractatus de Vulneribus Capitis* (Tract on Head wounds), by G. B. Cortesi with the engraved printer's device (logo). Messina, Pietro Brea, 1632.

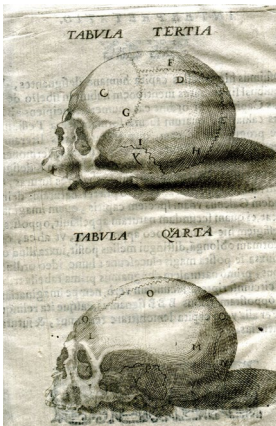


Figure 3 - Craniostenosis. Top: A possible representation of plagiocephaly; Bottom: A case of trigonocephaly. From: G. B. Cortesi. *Tractatus de Vulneribus Capitis*. Messina, Pietro Brea, 1632.

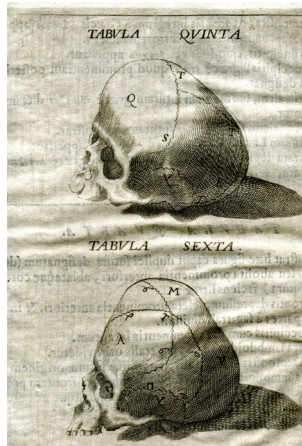


Figure 4 - Craniostenosis. Top: A possible representation of brachicephaly; Bottom: A case of Apert syndrome. From: G. B. Cortesi. *Tractatus de Vulneribus Capitis*. Messina, Pietro Brea, 1632.

**Tractatus de Vulneribus capitis** (On head wounds) [3] (**Figure 2**). The tract reports the original Greek text of Hippocrates on the same subject, with the Latin translation in front, followed by a commentary about the management of head wounds. It is illustrated with numerous engraved plates showing the surgical instruments required to perform craniotomy: the raspatory to abrade the skull bone, elevators for raising the depressed bone, and the trephine, with different types of burrs, for its perforation. The trephine is very similar to that described by Berengario da Carpi (1460-1530) in his book *De Fractura Calvae* (On Fractures of the Head), published in 1518 [4].

Interestingly, the work begins with the images of four different features of cranial vault deformities caused by alterations of the sutures. They are probably the first printed examples of craniostenosis reported in the literature. Although Cortesi does not coin a specific name for each of them, he does describe these anomalies and gives details about the cranial sutures.

The first image shows a cranial deformity with *O<sub>s</sub> frontis integrum* (Intact frontal bone) *prominentiam anteriorem faciens* (giving rise to anterior bulging) (**Figure 3 top**). It could most likely be referred to as plagiocephaly, although the profile view does not allow the evaluation of the contralateral side of the coronal suture. In presenting the following anomaly (**Figure 3 bottom**), Cortesi

writes *O<sub>s</sub> frontis depressum, abolita prominentia anteriori, ablataque coronali sutura* (slanting frontal bone, absence of anterior bulging and lack of coronal suture). It seems to be an example of trigonocephaly. The following image describes a cranial vault with *O<sub>s</sub> frontis prominens integrum. Occiput depressum* (intact and prominent frontal bone; slanting occiput) (**Figure 4 top**) - possibly a case of brachicephaly, cranial vault dysmorphism, secondary to bilateral premature fusion of the coronal suture. Finally, he reports the illustration of a skull with severe, multiple abnormalities. *O<sub>s</sub> frontis depressum. Ossa sincipitis in acutum ad verticem desinentia. O<sub>s</sub> occipitis depressum. Sutura ad auris terminans posteriorem regionem* (Flat frontal bone. The bones of the vault end acutely at the level of the vertex. Flat occiput. The auditory meatus is displaced downwards.) (**Figure 4 bottom**). Apparently, the representation of Apert syndrome.

More information regarding Giovanni Battista Cortesi and his role as general and plastic surgeon can be found in the book *Plastic Surgery: An illustrated History*, recently published by Riccardo F. Mazzola and Catherine B. Foss [5].

## REFERENCES

1. Gnudi MT, Webster JP. *The Life and Times of Gaspare Tagliacozzi, Surgeon of Bologna*. Milano, U. Hoepli, 1950
2. Cortesi GB. *Miscellaneorum Medicinalium decades denae* (Miscellany of Medicines, divided into ten decades). Messina, Pietro Brea, 1625
3. Cortesi GB. *De vulneribus capitis* (On head wounds). Messina, Pietro Brea, 1632
4. Mazzola RF, Mazzola IC. Treatise of skull Fractures by Berengario de Carpi. *J Craniofac Surg*. 2009; 20: 1981-4
5. Mazzola RF, Foss CB. *Plastic Surgery: An illustrated History*. Cham, Springer Nature, 2023

# NEUROSURGERY CORNER

*"This was probably the world's first remote-controlled shunt revision."*

## MY EXPERIENCE WORKING ON (AND OFF) MERCY SHIPS



**SHAIENDRA MAGDUM**  
UNITED KINGDOM

I recently received a message in my social media from Dr. Mark Shrime, Howard Global Surgery Professor, author, Chief Medical Officer of Mercy Ships, and an ENT surgeon. He reminded me (and posted on the platform) about a VP shunt revision we successfully performed in 2017 via video calling facilities using WhatsApp.

This was probably the world's first remote-controlled shunt revision. That this was possible was a surprise to me, given the improbability and many unknowns that could happen while executing it.

Before attempting the heroics, we tried but could not find an alternative solution, especially in a Lower Middle-Income Country (LMIC) such as Benin in West Africa.

The patient was a child with significant fronto-orbital encephalocele with dilating

ventricles. The visiting craniofacial team that included a plastic surgeon, a maxillofacial surgeon and me as neurosurgeon had repaired this large defect using a combined approach. ([ref - A Novel Surgical Technique for Large Frontoencephalocele Management: The Mercy Ships Approach. March 2021 FACE 2(2):273250162097932]

The main surgery went very well, but the repair was not sustained due to continued elevated intracranial pressure (ICP) and within ten days I had to insert a VP shunt due to rapid increase in head size and continued signs of raised ICP. At the time of shunt insertion, we had extensively photographed the whole procedure including correct form position and skin incision markings.

This child was doing very well, around four weeks after the shunt insertion, but when he

was about to be discharged home, he developed shunt malfunction which was highly likely to be the ventricular end.

Mark and I spoke extensively about the alternatives, asking the local neurosurgeon who had observed the craniofacial reconstructions with us during my two-week stint. Unfortunately, he was not available. I would need to assist from a remote location - in the UK.

I was confident that it was highly likely that the ventricular end was blocked, and that one only needed to open the cranial end of the wound and confirm that and then to replace like for like. The time zones in the UK and West Africa being the same, we could plan this process during a reasonable working day and time.

Overnight, Mark looked at the medical documentation and photographs of the surgery in preparation for his first VP shunt revision. It was important for me to be on the video call from the time of positioning of the patient because if I were only available after he had been draped, I would have little or no orientation of the position of the head and the insertion of the catheter and the brain would have been compromised.

I also needed assurance from the IT department onboard

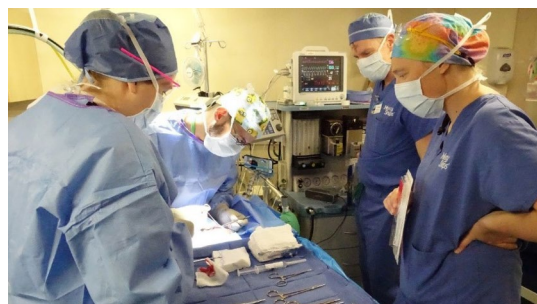
the hospital ship to give me enough bandwidth so that the video call would proceed without interruption.

It was the ventricle end that was blocked and the revision went according to plan with no further interventions required for this child.

I have been volunteering, mainly in West Africa, to help children and some adults with encephalocele repairs using this remote video set up, with the working team including a paediatric craniofacial neurosurgeon, a plastic surgeon, and a maxillofacial surgeon. This all happens on the largest civilian hospital ship run by Mercy Ships, USA. I have had significant experiences with a steep learning curve.

I had never personally met any of my team members, including the anaesthesiologist. Dr. Gary Parker, the resident maxillofacial surgeon who was the Chief Medical Officer at that time, reassured me about equipment and nursing care. Dr. David Chong, the plastic craniofacial surgeon from Melbourne, made me comfortable as soon as we had our first meeting. Both had been working on Mercy Ships for a long time.

Dr. Parker had six sincipital encephalocele patients screened, with initial CT scans done on the ship's scanner. These scans were sent to



*Figure 1 - Dr. Shrime revising the VP Shunt on a Mercy ship off the coast of Benin, Africa. Over his left shoulder is the mobile phone with the video live transmitted to me at Oxford University Hospitals in the UK.*



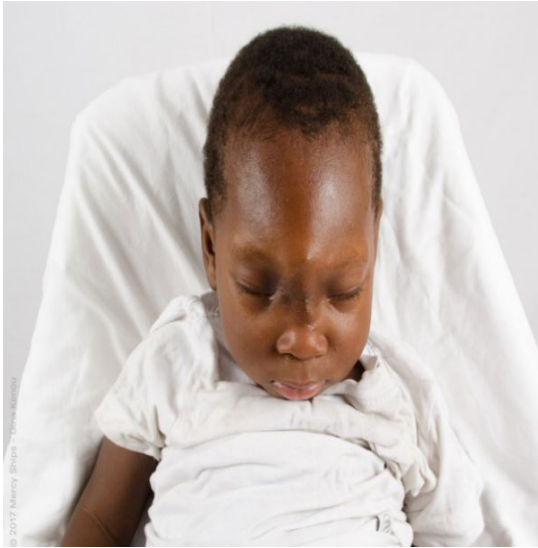

Figure 2 - Young Ich - Pre-Op



Figure 3 - Post Op, day 10, with raised ICP signs.

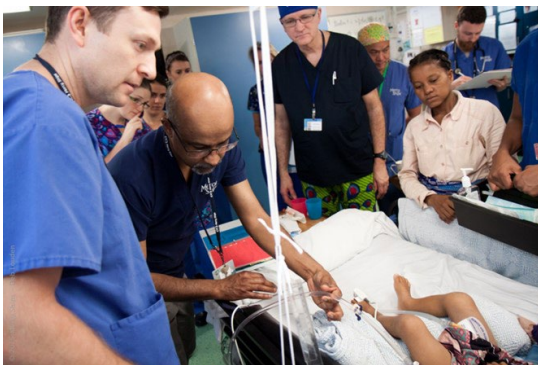

Figure 4 - Next day ward rounds. Note the amount of CSF in the catheter tube.

me to assist in preoperative planning which helped me to also get opinions from my craniofacial team in Oxford. In the western world, we do not often see sincipital encephaloceles so operating experience is limited.

Few of my past learning experiences have required me to innovate. Some of the required equipment and accessories are not always available onboard the ships, especially the less frequently used items. During one of my field trips, we ran out of the lumbar drainage system used to collect and measure cerebrospinal fluid (CSF). Instead, I used a sterile urinary collecting system to measure the hourly CSF output. This was connected to an IV stand with a one-foot ruler attached to gauge the CSF pressure.

There was no CSF in the chamber after twelve hours, but plenty of CSF was in the tube. As the calibre of the urinary collecting system is significantly capacious, there were at least 70 mls of CSF in the collecting tube.

There have been quite a few experiences and even some funny anecdotes working on this beautiful community hospital ship. It has also raised significant ethical questions regarding worldwide distribution of healthcare resources, our ability to provide safe and ongoing care in this remote setting,

and the role of “doctor” in healing children in LMIC’s.

I suggest that you will feel rewarded by being a bit adventurous and going beyond your own comfort zone. We have been gifted with surgical skills to make a difference.

*"We have been gifted with surgical skills to make a difference."*

# ORTHODONTICS UPDATE

*"In 1993, after years of device development and refinement, we introduced the NasoAlveolar Molding technique."*

## THE EVOLUTION OF NASOALVEOLAR MOLDING



**BARRY H. GRAYSON**  
UNITED STATES

In the summer of 1984, I read the article that was just published by Matsuo and Hirose - "Nonsurgical correction of congenital auricular deformities in the early neonate." At that moment, it occurred to me that molding the very important esthetic unit of distorted nasal cartilages, prior to the primary cleft surgical repair, was important and might enhance the surgical outcome. As I was having lunch with the Director of the Cleft Palate Team, Dr. Court Cutting, that afternoon, I took the article by Matsuo and Hirose with me to discuss and present my proposal of presurgical nasal cartilage molding. Court strongly supported the proposal and asked if I could combine it with the presurgical alveolar molding which was routinely practiced at that time. Thus, the birth of the idea and acronym NAM (NasoAlveolar Molding).

For decades, we have been challenged to provide ideal nasolabial esthetic results for children born with clefts of the lip, alveolus and palate. Both the unilateral and bilateral anomalies usually present severe nasal cartilaginous deformations and tissue deficiencies, almost impossible to correct by surgery alone. We theorized that as both ear and nasal cartilages are of hyaline nature, the principles of ear molding could be applied to the immature nasal cartilages. At the time, I was already using an acrylic molding plate to reposition the displaced alveolar and premaxillary segments. Therefore, it was an intuitive device modification to integrate an acrylic nasal stent to the alveolar molding plate that would gradually mold the distorted/deficient nasal structures.

The novel appliance design and approach integrated molding of the alveolar segments, nasal cartilages, nasal mucosa, and nasal soft tissue elements. In 1993, after years of device development and refinement, we introduced the NasoAlveolar Molding technique. The original NasoAlveolar molding device (NAM) incorporated acrylic nasal stent(s) and button(s) attached to an intraoral molding plate to concurrently mold the alveolar ridge, lift, and project the nasal tip while correcting the deformed nasal cartilages. The appliance is held in place and activated by an extraoral tape and elastic system. NAM is considered a significant paradigm shift in Presurgical Infant Orthopedics (PSIO), as for the first time in history, a neonatal device was designed to correct both the cleft alveolar segments and the nasal deformities. Distinct from traditional PSIO, the early practitioners of NasoAlveolar Molding (NAM) recognized the importance of reducing the severity of the cleft nasal deformity, a step considered essential to facilitate the primary cleft nasal repair and achieve a superior outcome. Later, the NAM appliance was utilized to achieve non-surgical elongation of the deficient columella of infants born with bilateral cleft lip and palate.

In 1995, we established the first ADA accredited craniofacial orthodontic

fellowship training program at New York University's Institute of Reconstructive Plastic Surgery. My first fellow, Dr. Pedro E. Santiago, assisted me in writing the first formal publications on this technique. During his fellowship training, Dr. Santiago suggested and implemented a critical modification to the device; the incorporation of a wire-armature to support the nasal stent. The new design facilitated nasal stent fabrication and its frequent adjustments. In 1996, he moved to his native Puerto Rico, and introduced three other modifications while preserving the original NAM objectives: 1) wire-based retention button(s), 2) the use of denture adhesive to stabilize the molding plate and move the alveolar and premaxillary segments more efficiently, and 3) minimal intra-plate acrylic reductions with no acrylic additions.

I have embraced Dr. Santiago's modifications and joined him in offering national and international hands-on workshops. We have trained thousands of NAM providers around the globe. To avoid confusion on the all too many iterations of the NAM device available in the scientific literature, we have decided to call this new device design and technique the Grayson-Santiago NAM protocol (GS-NAM). The device consists of wire and acrylic retention button(s) and nasal stent(s) attached

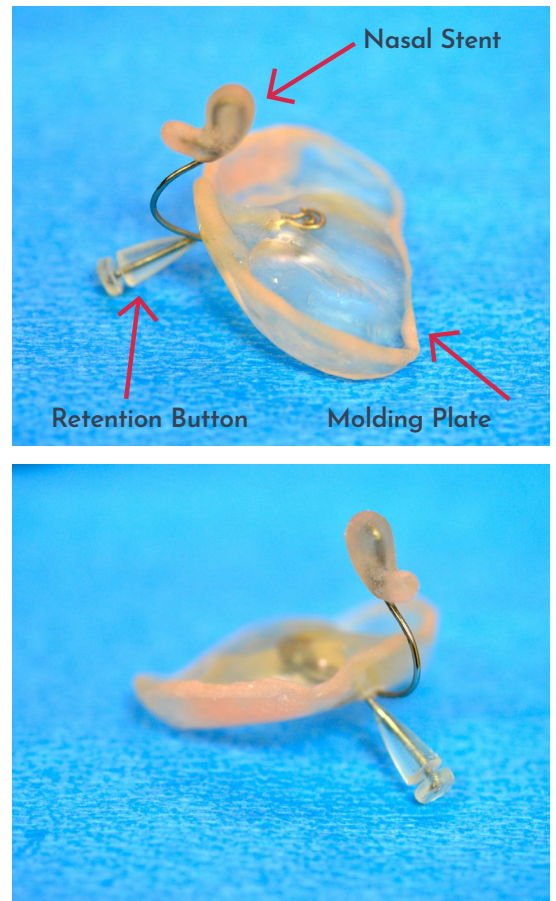


Figure 1: Unilateral GS-NAM Device - The unilateral GS-NAM device consists of a wire and acrylic retention button and nasal stent attached to an acrylic molding plate. The nasal stent has a goose neck shape to allow adequate space for lip taping and nasal stent adjustments. Notice that the borders of the molding plate and the upper and lower lobes of the nasal stent are covered by a layer of soft acrylic to prevent soft tissue irritation.

*"NAM is considered a significant paradigm shift in Presurgical Infant Orthopedics (PSIO)..."*

*"For decades, we have been challenged to provide ideal nasolabial esthetic results for children born with clefts of the lip, alveolus and palate."*

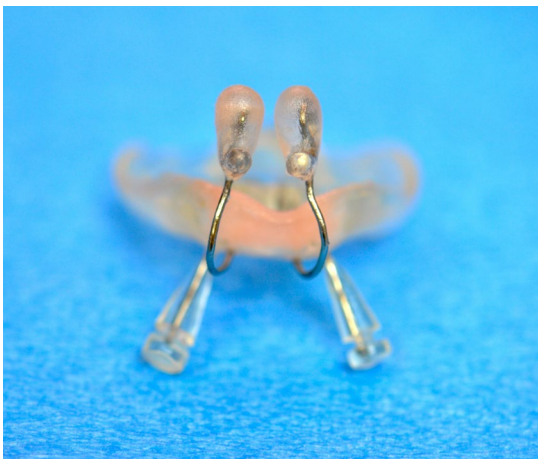
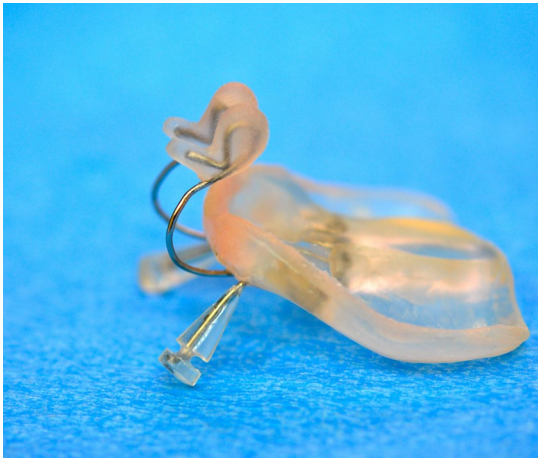

Figure 2: Bilateral GS-NAM Device - The bilateral GS-NAM device consists of 2 wire and acrylic retention buttons and nasal stents attached to the acrylic molding plate. As in the unilateral device, both stents have goose neck shape. From a frontal view, the stents diverge to accommodate the prolabium.

to a hard-acrylic alveolar molding plate, all of which serve to facilitate adjustments and reduce clinical treatment time (**Figures 1 and 2**). This modified approach also incorporates the use of denture adhesive and minimal intra-molding plate acrylic adjustments, increasing clinical effectiveness and efficiency. As in the original design, the direction and magnitude of force is controlled using an extraoral tape and elastic system.

In addition to facilitating superior surgical results for the lip, alveolus, and nose, the application of GS-NAM has in many cases reduced the need for extensive surgical undermining of periosteum and eliminated the need for surgical columella reconstruction, thus eliminating scar tissue in the columella and its impact on growth of the nose.

We are currently in the final stage of preparation for a comprehensive, detailed, and illustrated book on GS-NAM. We encourage the reader to carefully follow the GS-NAM device fabrication and clinical protocol as it presents the synthesis of many years of experience practicing and refining GS-NAM. Unfortunately, the literature is replete with seemingly endless variations of NAM that often have diluted the quality and predictability of its outcomes. For this reason, the book will

present a strong argument to master the classical GS-NAM technique and protocol before introducing variations of one's own.

We are confident that when implemented correctly, the GS-NAM appliance and treatment protocol will not only provide your team with the necessary tools to excel in its clinical outcomes, but will positively impact your patients' and their families' psychosocial well-being and quality of life.

## REFERENCES

1. Matsuo, K, Hirose, T et al. Nonsurgical correction of congenital auricular deformities in the early neonate: a preliminary report. *Plastic and Reconstructive Surgery* 73 (1), 38-51, 1984
2. Grayson, BH and Santiago, PE. Presurgical Orthopedics for Cleft Lip and Palate. In *Grabb and Smith's Plastic Surgery*, fifth edition, chapter 20, pages 237-243. Lippincott-Raven Publishers, Philadelphia, 1997.
3. Cutting, C, Grayson B, Brecht, L, Santiago, P, Wood, R and Kwon, S. Presurgical Columellar Elongation and Primary Retrograde Nasal Reconstruction in One-Stage Bilateral Cleft Lip and Nose Repair. *Plastic and Reconstructive Surgery*, 101:3, 630, 1998.
4. Grayson, BH, Santiago, PE, Brecht, LE and Cutting, CB. Pre-surgical NasoAlveolar Molding in Patients with Cleft Lip and Palate. *Cleft Palate-Craniofacial Journal*, 36:6, 486-98, 1999.
5. Santiago, PE, Grayson, BH, Cutting, CB, Gianoutsos, MP, Brecht, LE and Kwon, SM. Reduced Need for Alveolar Bone Grafting by Presurgical Orthopedics and Primary Gingivoperiosteoplasty. *Cleft Palate-Craniofacial Journal*, 35:1, 77, 1998.

# DIGITALIZING THE INTERNATIONAL SOCIETY OF CRANIOFACIAL SURGERY THROUGH RESIDENT AND FELLOW ENGAGEMENT

*"... ISCFS is continuing to shape the future of craniofacial surgery."*

---



**BEN MASSENBURG**  
UNITED STATES

In an era marked by technological advancement and digital connectivity, the International Society of Craniofacial Surgery (ISCFS) is leveraging the enthusiasm and expertise of its Resident and Fellow members to propel the society into the digital age. Through webinars and collaborative initiatives, ISCFS is fostering a dynamic exchange of knowledge, embracing innovation, and nurturing our vibrant community of craniofacial surgeons.

Our first foray into regular webinars and social media engagement featured Dr. Richard Hopper, Dr. David Dunaway, and Dr. Irene Mathijssen who presented a case-based discussion on **Management of the Apert Midface** on April 22. Recognizing the invaluable insights and fresh perspectives of Residents and Fellows, the society is inviting active participation in case presentations alongside seasoned Attendings.

As these webinars will be world-wide, the dates and times will vary based on location, and we will rotate the times with each subsequent webinar.

Future webinar topics will include anterior cranial distraction, facial contouring, correction of hypertelorism, posterior vault distraction osteogenesis and Chiari malformations, and orthognathic surgery. We are encouraging these to be case-based, so the audience has an opportunity to ask detailed questions about the workup, indications, surgical maneuvers, and post-operative care pathways for midface advancement.

Beyond webinars, the ISCFS is actively engaging Resident and Fellow members in other avenues of contribution, including newsletter publications. Recognizing their unique perspectives and scholarly potential, the society welcomes submissions from Residents and Fellows interested in sharing their insights, experiences, and

*"...ISCFS is fostering a dynamic exchange of knowledge, embracing innovation, and nurturing our vibrant community of craniofacial surgeons."*

---

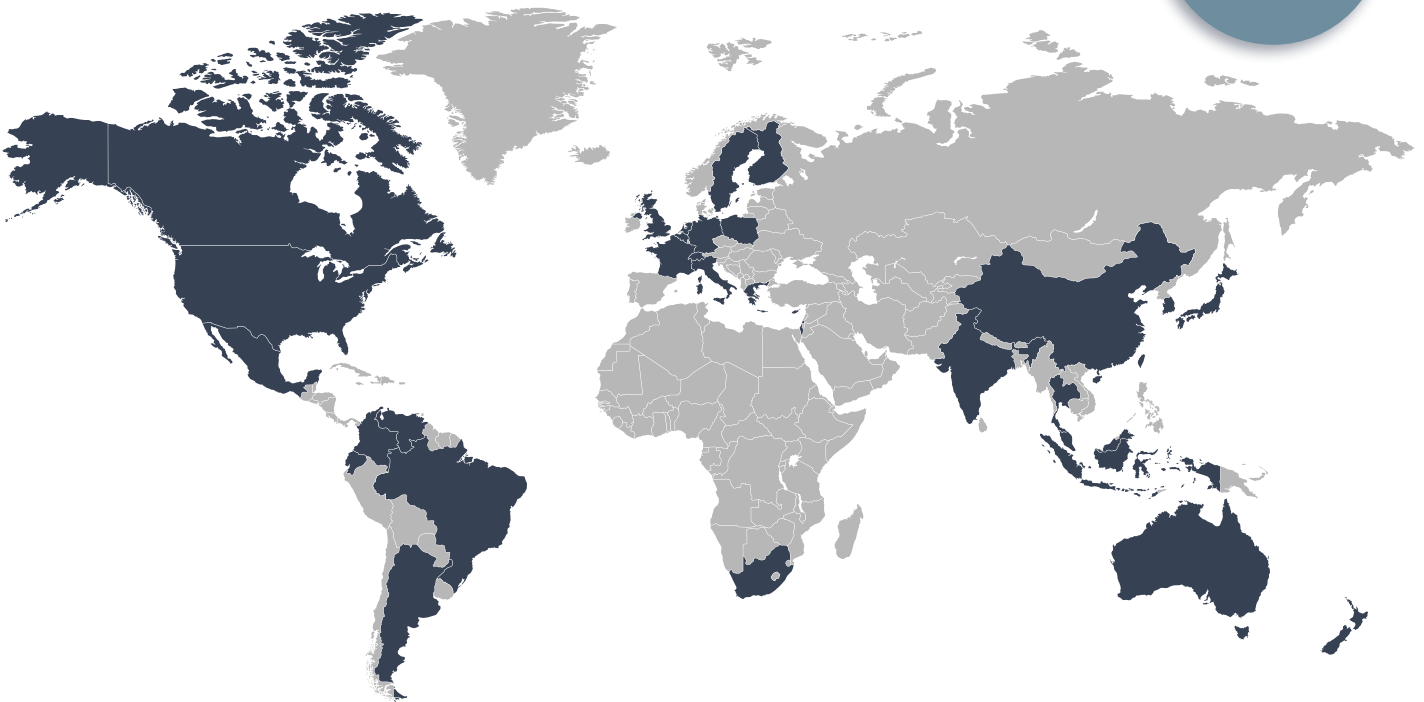
research findings with the broader craniofacial surgery community. Please contact me at [ben.massenburg@gmail.com](mailto:ben.massenburg@gmail.com) if you are interested in contributing to this column.

The involvement of Residents and Fellows in ISCFS initiatives extends beyond individual contributions to collective engagement in shaping the society's future. The integration of Resident and Fellow membership into


the ISCFS digital initiatives underscores the society's dedication to innovation, inclusivity, and knowledge exchange. By bridging generations and embracing technology, ISCFS is continuing to shape the future of craniofacial surgery.

**MEMBERS WILL VOTE IN JUNE TO ADMIT NEW MEMBERS.  
SUBMIT YOUR APPLICATION BY MAY 31.**

**MEMBERS  
FROM 33  
COUNTRIES**



# BECOME AN ISCFS MEMBER



We welcome membership applications in Active, Associate, Corresponding, Orthodontic, Research, and Resident/Registrar/Fellow categories and have created a simple on-line process. Current member specialties include plastic, craniofacial, oral and maxillofacial surgeons, neurosurgeons, orthodontists, otorhinolaryngologists, dentists, and those involved in related research.

There is a \$75 application fee and annual fees are \$150 for Active/Associate members and \$50 for Resident/Registrar/Fellow members. Our website includes information about qualifications for membership and frequently asked questions at this link: <https://iscfs.org/membership/>

## MEMBERSHIP BENEFITS

- Global Visibility
- International Recognition
- Reasonable yearly membership fees
- Reduced congress registration fee at the biennial international ISCFS Congress
- Professional networking

## JOIN US!

ACTIVE/ASSOCIATE

RESIDENT/REGISTRAR/  
FELLOW



INTERNATIONAL  
SOCIETY OF  
CRANIOFACIAL  
SURGERY

[www.iscfs.org](http://www.iscfs.org)

# EVENT CALENDAR

## AMERICAN CLEFT PALATE CRANIOFACIAL ASSOCIATION (ACPA)

Location: Sheraton Downtown,  
Denver, USA

Date: April 9-13, 2024

Website: [https://acpacares.org/  
annual-meeting/](https://acpacares.org/annual-meeting/)

## AMERICAN SOCIETY OF CRANIOFACIAL SURGEONS (ASCFS)

Location: Sheraton Downtown,  
Denver, USA

Date: April 11-13, 2024

Website: [https://ascfs.org/  
Professionals/](https://ascfs.org/Professionals/)

During the ACPA conference

## XVII CONGRESSO BRASILEIRO DE CIRURGIA CRÂNIO-MAXILO-FACIAL (ABCCMF)

XIV CONGRESSO BRASILEIRO DE  
FISSURAS LÁBIO PALATINAS E  
ANOMALIAS CRANIFACIAIS (ABFLP)

## 5TH CONGRESS LATINAMERICAN CRANIOFACIAL ASSOCIATION (LATICFA)

Location: Royal Palm Hall -  
Campinas/SP, Brasil

Date: August 29-31, 2024

Website: [www.abccmf.org.br/  
congresso](http://www.abccmf.org.br/congresso)

## EUROPEAN SOCIETY OF CRANIOFACIAL SURGERY BIENNIAL CONFERENCE (ESCFS 2024)

Location: Scandic Marina  
Congress Center, Helsinki,  
Finland

Date: September 5-7, 2024

Website: <http://www.escfs.org/>

## 27TH EACMFS CONGRESS

Location: Rome, Italy

Date: September 17-20, 2024

Website: [www.eacmfs.org](http://www.eacmfs.org)

Pre-Congress Day:

September 16, 2024

## THE 82ND CONGRESS OF KOREAN SOCIETY OF PLASTIC AND RECONSTRUCTIVE SURGEONS

## THE 27TH KOREAN CLEFT PALATE- CRANIOFACIAL ASSOCIATION

Location: Grand Intercontinental  
Seoul Parnas, Seoul, Korea

Date: November 17-19, 2024

Website: [www.kcpca.or.kr](http://www.kcpca.or.kr)

## SAVE THE DATE 21ST CONGRESS ISCFS CONGRESS

Location: Shanghai, China

Date: October 27-30, 2025

Website: [www.iscfs.org](http://www.iscfs.org)

---

To submit a meeting to the calendar in our next issue,  
send the following information to [admin@iscfs.org](mailto:admin@iscfs.org):  
Meeting Title, Location, Dates, Website.



## ISCFS MANAGEMENT

### ISCFS COUNCIL

XIONGZHENG MU, China - President

IRENE MATHIJSSSEN, The Netherlands - Vice President

JESSE TAYLOR, United States - Secretary-Treasurer

RICHARD HOPPER, United States - Immediate Past President

DOV GOLDENBERG, Brazil - Council

JAY JAYAMOHAN, United Kingdom - Council

CASSIO E. RAPOSO DO AMARAL, Brazil - Council

MARIANA SABAS, Argentina - Council

DAVINDER SINGH, United States - Council

ERIC ARNAUD, France - Parliamentarian

### ISCFS SOCIETY MANAGEMENT TEAM

BARBARA BOELD, Germany - Executive Director

CATHERINE FOSS, United States - Administration

VERENA REINMUTH, Germany - Administration



**INTERNATIONAL  
SOCIETY OF  
CRANIOFACIAL  
SURGERY**

#### LEGAL ADDRESS

10 Penn Tower, 3400 Spruce Street  
Philadelphia, PA, 19104  
United States

#### MAILING ADDRESS

**US:**  
38 Rayton Road  
Hanover, NH 03755 USA

#### EUROPE:

Reitmorstrasse 25  
80538 Munich, Germany

**US email:** [admin@iscfs.org](mailto:admin@iscfs.org)

**Europe email:** [office@iscfs.org](mailto:office@iscfs.org)

[www.iscfs.org](http://www.iscfs.org)



## ISCFS NEWSLETTER EDITORIAL BOARD

### EDITOR

JESSE TAYLOR, United States

### MANAGING EDITOR

CATHERINE FOSS, United States

### GRAPHIC DESIGNER

RUDITE TAUNINA, Germany

### NEUROSURGERY EDITOR

JAY JAYAMOHAN, United Kingdom

### HISTORY EDITOR

RICCARDO MAZZOLA, Italy

### RESIDENTS/FELLOWS REPRESENTATIVE

BEN MASSENBURG, United States

### EXECUTIVE DIRECTOR

BARBARA BOELD, Germany



**DISCLAIMER:** This newsletter presents information and opinions pertinent to medical professionals. It does not provide advice concerning specific diagnoses and treatments of individual cases and is not intended for use by the lay person. ISCFS is not responsible for facts, opinions, and other information presented by the authors or advertisers in this newsletter or otherwise. Readers are strongly advised to confirm that the facts, opinions, and other information comply with the latest legislation and standards of practice. ISCFS, the editors, the authors, and the publisher will not be responsible for any errors or liable for actions taken as a result of facts, opinions, and other information expressed in this newsletter or otherwise. Copyright © 2024 by the International Society of Craniofacial Surgery, Inc. All rights reserved. Contents may not be reproduced in whole or in part without written permission of ISCFS.



**ISCFS 2025**  
**27-30 OCTOBER**  
Shanghai, China | [www.iscfs.org](http://www.iscfs.org)

ISCFS PRESIDENT: DR. XIONGZHENG MU



**SAVE THE DATE**

**Dr. Xiongzhen Mu and Dr. Xudong Wang  
invite you to Shanghai, China for the 21st  
Congress of the ISCFS in **October 27-30, 2025.****



**Dr. Xiongzhen Mu**  
2023-2025 ISCFS President



**Dr. Xudong Wang**  
Assistant Dean, Shanghai  
People's 9th Hospital



**SEE YOU IN  
SHANGHAI!**