

International Society of Craniofacial Surgery

ISCFS NEWSLETTER

Volume 1 | Number 3



IN THIS ISSUE:

**SHANGHAI
FACTS**

**WINDOW INTO
HISTORY**

**HOW I DO IT:
MANAGEMENT
OF UNICORONAL
CRANIOSYNOSTOSIS**

JULY 2024

MESSAGE FROM THE EDITOR

Dear Members and Friends of the International Society of Craniofacial Surgery,

As the summer months unfold, it brings me great pleasure to welcome you to this third edition of our newsletter. In this issue, we spotlight significant upcoming events and share the latest advancements and discussions in the field of craniofacial surgery. Our collective journey as a society is marked by continuous learning, collaboration, and innovation - and the forthcoming months promise to be particularly momentous.

HIGHLIGHTING UPCOMING MEETINGS
ESCFS Meeting in Helsinki, Finland - September 5-7, 2024
 Our first noteworthy gathering will be the European Society of Craniofacial Surgery (ESCFS) meeting taking place in the vibrant city of Helsinki in early September, hosted by the President, Junnu Leikola. This event will provide a platform for experts and emerging professionals alike to share their latest research, surgical techniques, and

clinical experiences. The scenic backdrop of Helsinki, with its blend of modernity and rich cultural heritage, offers the perfect setting for our intellectual and professional exchange. We anticipate a diverse array of presentations and discussions that will enrich our collective knowledge and inspire new approaches in our field. <https://konffaevents.fi/en/escfs-2024/>

ESCMFS Meeting in Rome, Italy - September 17-20, 2024
 Shortly after Helsinki, we will convene in the eternal city of Rome for the European Society of Craniomaxillofacial Surgery (ESCMFS) Congress. Scheduled for mid- September, this gathering promises to delve into the intricacies of craniomaxillofacial surgery exploring cutting-edge research, innovative surgical practices, and comprehensive patient care strategies. Rome's timeless allure, coupled with its status as a center of medical history, will undoubtedly enhance our conference experience. The event will also serve as an excellent opportunity

TABLE OF CONTENTS

| | |
|--|----|
| Message from the Editor Jesse Taylor | 02 |
| How I Do It: Management of Unicoronal Craniosynostosis Diego Caycedo Marcela Cabal Jesse Taylor Jeffrey A. Fearon | 04 |
| NEW! Webinar Access in Members' Area of ISCFS Website | 10 |
| Shanghai Facts Xianxian Yang | 11 |
| Window Into History Riccardo F. Mazzola | 14 |
| Neurosurgery Corner Jay Jayamohan | 16 |
| Orthodontics Update Mariana Sabás María Ana Muñoz | 18 |
| Residents & Fellows Corner Rodrigo Andrés Penagos-Luna | 21 |
| New Members | 23 |
| Event Calendar | 25 |

for networking, fostering collaborations that will drive the future of our specialty.

<https://www.emma.events/eacmfs2024>

19th ISCSF Congress in Shanghai, China - October 28-30, 2025

Looking ahead, we will be thrilled to welcome everyone to the 19th ISCSF Congress in Shanghai in October 2025, to be chaired by President Xiongzhen Mu. This major event will bring together the global craniofacial surgery community for an unparalleled exchange of knowledge and expertise. Shanghai, with its dynamic blend of tradition and innovation, will host this pivotal meeting, offering a unique cultural and professional experience. We are preparing an extensive program that includes keynote lectures from leading figures in the field, comprehensive workshops, and interactive free paper and poster presentation sessions designed to address the most pressing challenges and advances in craniofacial surgery.

Embracing the Future Together

As we prepare for these significant gatherings, it is important to reflect on the progress we have made in the last forty years, and the potential that lies ahead. The ISCSF remains committed to advancing the field of craniofacial surgery through education, research, and global collaboration. Each

educational event that we host is a testament to our collective dedication to improving patient outcomes and pushing the boundaries of what is possible.

We encourage all members to actively participate in these events, whether by presenting your work, engaging in discussions, or simply absorbing the wealth of knowledge that will be shared. Your involvement is crucial to the success of our society and the ongoing evolution of our field.

In closing, I extend my heartfelt gratitude to all members of the ISCSF for your unwavering commitment and contributions. Together, we are shaping the future of craniofacial surgery, one innovative step at a time. Let us look forward to an enriching and inspiring series of meetings, and to the continued growth and success of our society.



JESSE TAYLOR
UNITED STATES



HOW I DO IT: MANAGEMENT OF UNICORONAL CRANIOSYNOSTOSIS

TWO-CENTER SPIRAL OSTEOTOMIES AND TELESCOPING FOR THE MANAGEMENT OF UNICORONAL CRANIOSYNOSTOSIS



DIEGO CAYCEDO
COLOMBIA

At our Center, we employ various treatments for anterior plagiocephaly, depending on the severity and underlying cause of the condition. Some of the types of surgery include:

- Cranial reshaping surgery: This is the most common option to correct anterior plagiocephaly. Cranial



MARCELA CABAL
COLOMBIA

bones are remodeled to correct the deformity, with the use of both osteotomies and suturectomies to achieve a more symmetrical cranial shape.

- Endoscopic surgery: In some less severe cases, endoscopic surgery may be chosen which involves making smaller incisions and using an



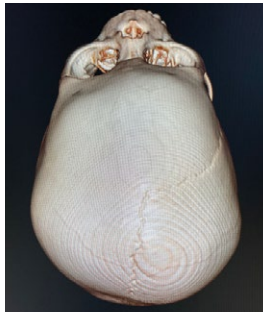
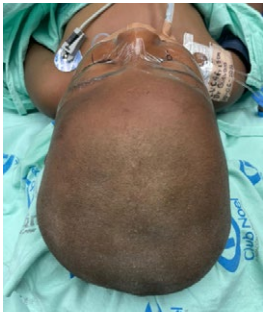
Image 1, a and b, pre-surgical views

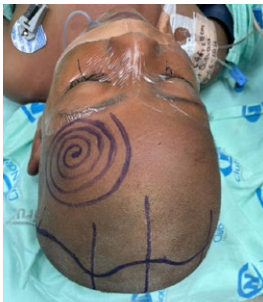

Image 2, Surgical Planning

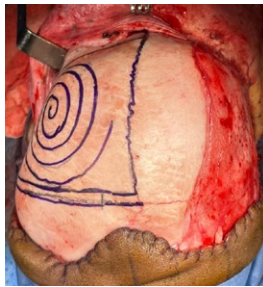


Image 3, Intra surgical view: Suturotomy and spiral osteotomies design

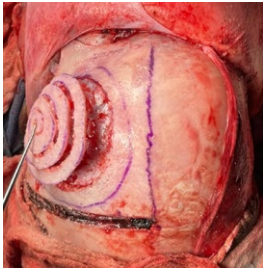

Image 4, Coronal suturotomy with two-centered spiral osteotomies and telescoping projection

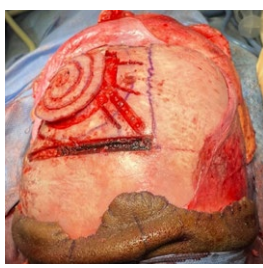

Image 5, Spiral osteotomies and telescoping stabilization with absorbable plates

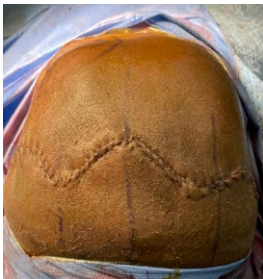

Image 6, immediate post-surgical view with cranial symmetry and correction of unicoronal synostosis

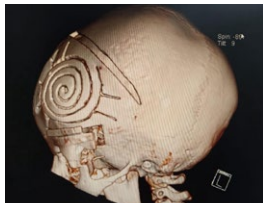


Image 7, Post-surgical 3D tomography

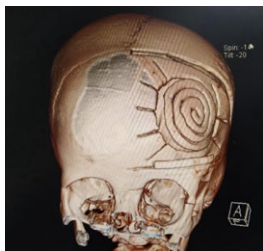

Image 8, Post-surgical 3D tomography

endoscope to reshape the bones of the skull.

- Distraction osteogenic surgery: In more severe cases of anterior plagiocephaly where there is significant deformity in the skull and bone formation surgery is required to achieve adequate results. Osteotomies are performed and gradually separated using an external distraction device. Over time, this process stimulates the growth of new bone, allowing a progressive correction of the deformity.

The case shown here is our favored treatment for anterior plagiocephaly, when asymmetry and cranial alterations indicates surgery. The technique consists of cranial remodeling with hemicoronal suturotomy and unilateral fronto-orbital advancement, using the frontonasal junction at the midline of the bar as a pivot. For the remodeling and symmetrization of the flattened frontal side, a two-center spiral osteotomy is designed and cut as bony flaps that are modified with telescoping projection vectors, and stabilized with absorbable plates. This cranioplasty design allows the

brain to expand gradually and the flattened side to progressively achieve a functional and symmetrical anatomical condition similar to that in the contralateral side. We have used this technique in the majority of our cases over the past two decades and we find that it holds up well over time.

"Cranial reshaping surgery: This is the most common option to correct anterior plagiocephaly. Cranial bones are remodeled to correct the deformity, with the use of both osteotomies and suturotomy to achieve a more symmetrical cranial shape."

FRONTO-ORBITAL DISTRACTION OSTEOGENESIS (FODO)

"Depending on the severity of the presentation, a horizontal nasofrontal osteotomy is performed via the blepharoplasty incision."



JESSE TAYLOR
UNITED STATES

After embracing open fronto-orbital distraction osteogenesis (FODO) for almost a decade, we have evolved to performing a similar operation through minimal incisions with the aid of an endoscope (endo-FODO). In the endo-FODO approach, exposure is obtained through three small incisions: a chevron at the anterior fontanelle, a chevron at the ipsilateral pterional region, and an ipsilateral upper lateral blepharoplasty incision (**Figure 1**).

Through the pterional incision, the posterior half of the temporalis muscle is released, exposing the infratemporal fossa and lateral orbit. Using both direct visualization and an endoscope from the anterior fontanelle incision, a

limited coronal suturectomy is performed, and a 2-cm pterional window (**Figure 2**) is created just anterior to the suturectomy as a working port for the sphenoid and periorbital osteotomies. The sphenoid wing and orbital roof osteotomies are performed through the pterional working port most commonly with an ultrasonic scalpel, with the orbital contents protected by a malleable retractor via the upper blepharoplasty incision (**Figure 2**). Depending on the severity of the presentation, a horizontal nasofrontal osteotomy is performed via the blepharoplasty incision.

Finally, a contralateral partial frontal bone osteotomy is made to perform like a hinge such

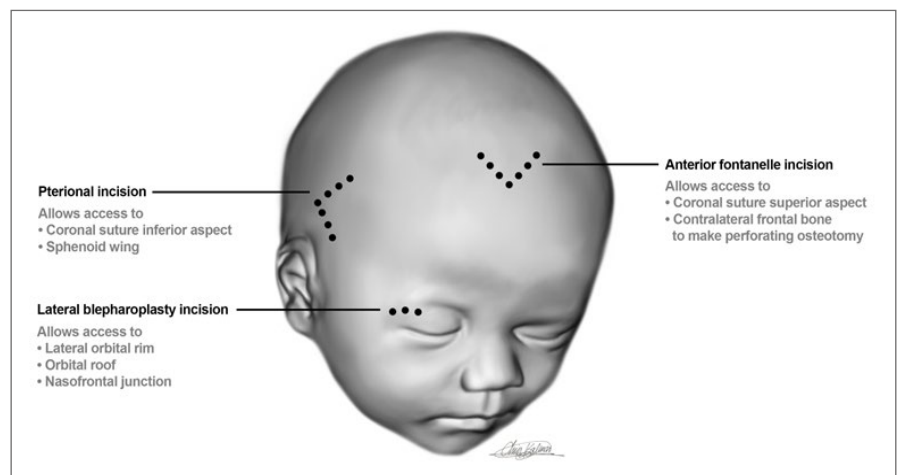


Figure 1. Diagram demonstrating incisions for endo-FODO

that the ipsilateral orbit and forehead can be directed sagittally forward, and slightly inferiorly, by a single temporally based, semi-buried distractor placed across the suturectomy (**Figure 2**). To facilitate distractor removal, especially of the anterior baseplate, we have employed resorbable brads instead of titanium screws in the distractor baseplates. **Figure 3** shows a patient pre-op, with **Figure 4** in consolidation, and **Figure 5** showing the patient two years after Endo-FODO.

"Through the pterional incision, the posterior half of the temporalis muscle is released, exposing the infratemporal fossa and lateral orbit."

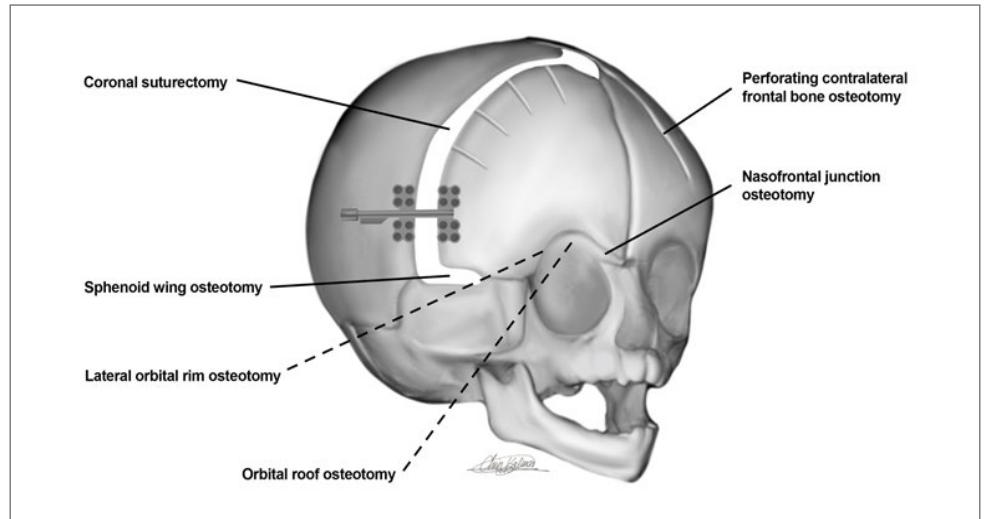


Figure 2. Osteotomy pattern for Endo-FODO.

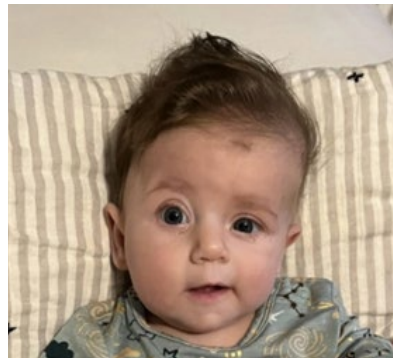

Figure 3. Pre-op.



Figure 4. In Consolidation.

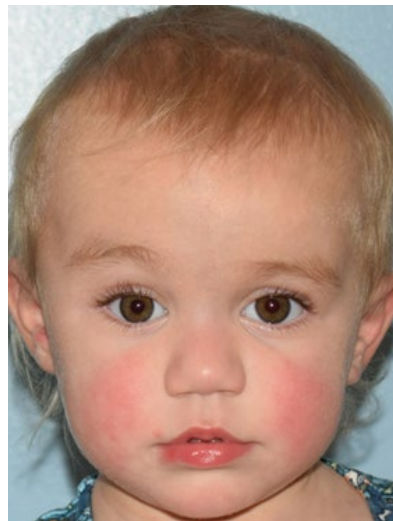

Figure 5. Two years post-op.

UNICORONAL CRANIOSYNOSTOSIS

"The surgical goals are two-fold: 1. To enlarge the skull; and 2. To normalize appearance."



JEFFREY A. FEARON
UNITED STATES

The successful treatment of unicoronal craniosynostosis is predicated on a complete understanding of the associated three-dimensional changes. The presenting clinical findings include: one eye appearing more open than the other, arising from the impaired descent of the supraorbit, and deviation of the nasal root to the affected side. The bird's-eye view reveals an ipsilateral anterior/posterior reduction in skull length, with a corresponding contralateral over-growth. Lastly, the coronal fusion produces a reduction in skull height, with a compensatory elevation on the opposite side.

The surgical goals are two-fold: 1. To enlarge the skull; and 2. To normalize appearance. Achieving a superior long-term result requires recognition of, and compensating for, the predictable growth impairments that follow any surgical intervention. This knowledge impacts operative decision-making with respect to both surgical timing and the necessary degree of over-correction. Ideally, the selected technique should involve the smallest overall treatment burden, the lowest surgical complication rate, and the fewest operative interventions.

At the Craniofacial Center in Dallas, unicoronal synostosis corrections are recommended sometime between 11 and 15 months of age, following the peak growth spurt of the brain. Preoperative iron supplementation and erythropoietin injections are advised. Intraoperative blood recycling is utilized in all cases and hypotensive anesthesia is avoided to safeguard cerebral circulation. A wavy line, limited length, coronal incision is performed, and scalp flaps are elevated with a supra-periosteal dissection. Anterior and posterior pericranial flaps are then raised, incorporating the temporalis muscles with the anterior flap. A roughly 6 x 20 cm bone flap is harvested from the posterior parietal region to reconstruct the entire forehead as a single-segment (**Figure 1**). The new supraorbit is designed along the posterior aspect of this bone flap, taking advantage of the over-growth occurring on the unaffected side of the skull, which when rotated to reconstruct the entire frontal bone will produce both an antero-lateral over-correction, as well an increase in forehead height on the affected side (**Figure 2**). Prior to placement, the native frontal

bone is removed down to the anterior skull base; however, no intraorbital dissection is necessary. If the rotated single-segment appears more over-corrected than desired, kerfing cuts are made to allow for a reduction in project following redraping of the temporalis muscle (**Figure 3**).

With the new single-segment appropriately repositioned, markings are made laterally on either side in the sphenotemporal regions for intended removal, to permit an end-to-end inset that is secured with PDS (Ethicon) absorbable sutures (**Figure 4**).

Supplementary sutures can be added between the new lateral supraorbits and the native lateral orbital rims for additional stability. The posterior cranioplasty is then addressed, utilizing the former frontal bones and additional split cranial bone grafts to completely reconstruct the donor site and all associated defects created by the overcorrected skull expansion. All larger grafts are secured with resorbable sutures, while smaller grafts are secured with Surgicel (Ethicon) (**Figure 5**). The pericranial flaps are resuspended and the scalp is closed in two layers with dissolving sutures. The scalp is shampooed; no drainage tubes or external bandages are necessary.

As performed at our center, incision to completion of closing averages 120 minutes.

Patients are maintained on I.V. dexmedetomidine overnight in the PICU. A postoperative non-narcotic ERAS protocol is utilized with alternating I.V. acetaminophen and ketorolac, every 3 hours, supplemented with I.V. diphenhydramine and lorazepam, as needed. Ondansetron is routinely administered every 6 hours to suppress post-anesthetic nausea. Patients are transferred to the floor the next morning for additional overnight observation. Once tolerating oral feeds on the second postoperative day, they are shampooed and discharged home. As experience is gained, surgeons can expect improved aesthetic results, with shorter operative times.

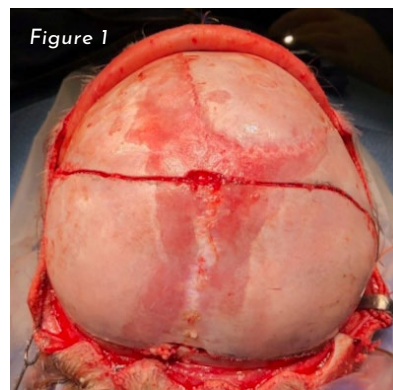


Figure 1

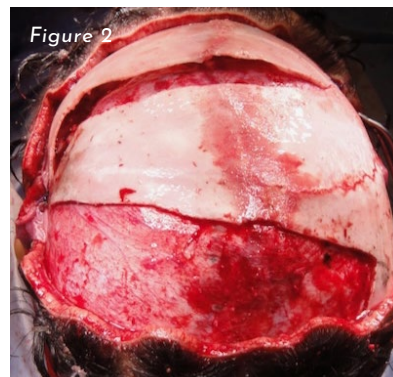


Figure 2

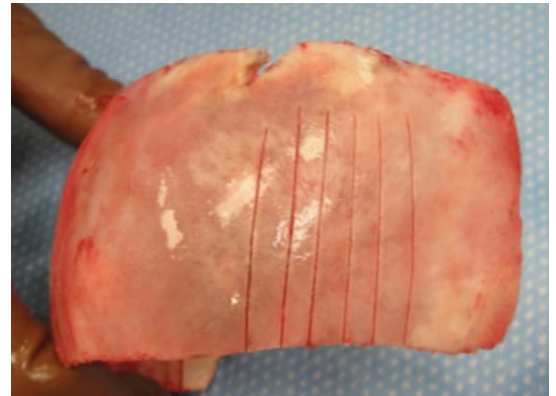


Figure 3

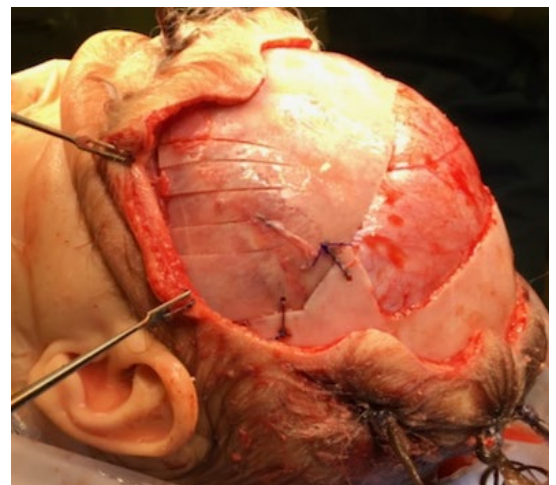


Figure 4

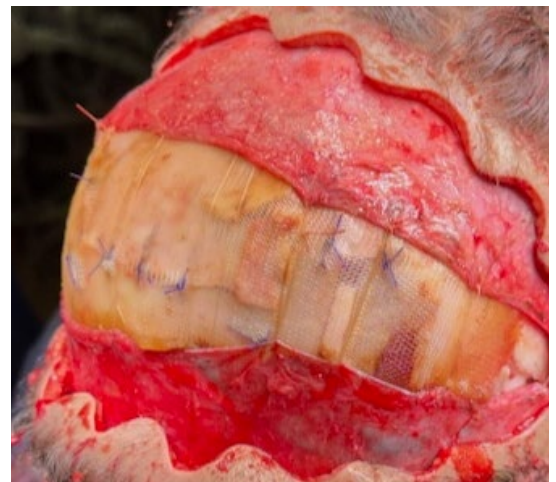


Figure 5

NEW! WEBINAR ACCESS IN MEMBERS' AREA OF ISCFS WEBSITE

Our website manager is developing a new password protected Members' Area that will be available in a few months.

To begin, this new feature will include recordings of previous webinars and a member directory.

Current members will create and update their own directory listings with the option to make specific information available to the public.

We encourage non-members to consider joining the ISCFS to take advantage of the marketing

aspect of the member directory and to have full access to the webinars, especially if the timing of live programs is not convenient. We also welcome suggestions for other information to be included in the Members' Area at: admin@iscfs.org

Our June webinar on **ANTERIOR CRANIAL VAULT DISTRACTION FOR UNICORONAL CRANIOSYNOSTOSIS** was presented by **Drs. Jesse Taylor** (US) as Moderator, **Amanda Gosman** (US), **Jong Wo Choi**

(South Korea) and **Lars Kölby** (Sweden). With more than 200 attendees, a lively discussion followed the three excellent lectures.

For the time being, these quarterly webinars will be offered for free, will move to a different time zone each time, and will remain available to members on our website.

ISCFS WEBINAR: CHALLENGES AND PEARLS IN MANAGING ORBITAL HYPERTELORISM

SEPTEMBER 24, 2024 | 6 PM EST



INTERNATIONAL
SOCIETY OF
CRANIOFACIAL
SURGERY



21ST ISCFS CONGRESS

"Shanghai is developing toward an internationally influential digital city..."



Provided by
XIANXIAN YANG
CHINA



SHANGHAI FACTS

Shanghai, a municipality directly under the central government of China, is a modern international metropolis with a spirit of inclusiveness, pursuit of excellence, broad-mindedness, and humility. Located at the estuary of the Yangtze River in East China and facing the Pacific Ocean, Shanghai forms part of the Yangtze River Delta, one of China's most robust, open and innovative regions.

As China's largest economic powerhouse and an important international financial center, Shanghai achieved a GDP of 4.72 trillion yuan in 2023, up five percent year-on-year. Shanghai is also a leading international trade and consumption center. In 2023, Shanghai's total imports and exports amounted to 4.21 trillion yuan, marking a record high, while the city's total retail sales of consumer goods surged by 12.6 percent.

Shanghai is an important global shipping center and an open hub, implementing the RCEP (Regional Comprehensive Economic

Partnership) agreement and accelerating the construction of the Waigaoqiao and Hongqiao national import trade promotion and innovation demonstration zones.

The city is also making significant progress in building an international science and technology innovation center. The proportion of research and development expenditure to the GDP was around 4.4 percent in 2023, while there were 50.2 high-value invention patents per 10,000 people in June of 2024. Shanghai is developing toward an internationally influential digital city, strengthening the foundational support for urban digital transformation.

It is one of the country's most international cities, with 956 headquarters of multinational companies and 561 foreign-invested R&D centers established by the end of 2023.

Shanghai is also a world-renowned cultural center and international travel destination with 239 public libraries,

"Shanghai, a municipality directly under the central government of China, is a modern international metropolis with a spirit of inclusiveness, pursuit of excellence, broad-mindedness, and humility."

165 museums and 100 art galleries, and a transport system that is becoming more efficient, with its metro network reaching 831 kilometers. The city has a complete education system, with 68 higher-education institutions, 900 secondary schools and 664 primary schools. In the future, Shanghai will showcase its character of "International, Innovative and Inclusive" focus on high-quality development

and turn itself into an international economic, financial, trade, shipping, and science and technology innovation center, as well as a global digital city with great influence.

SOURCES:

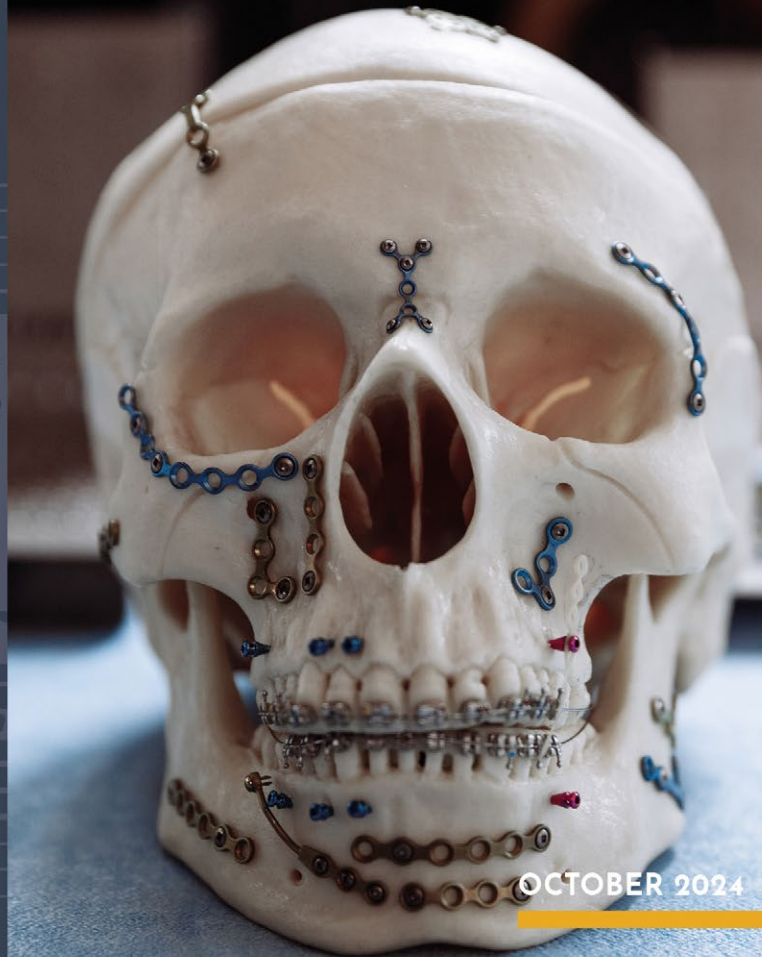Shanghai Municipal Government Work Report, Shanghai Customs, whb.cn, Shanghai Basic Facts 2023, Shanghai Almanac 2023 - Updated: March 5, 2024

ISCFS NEWSLETTER

Volume 1 | Number 4

HOW I DO IT: Pterygomaxillary Dysjunction of Lefort I, III and Monobloc

To submit an article of 750-1000 words with up to 5 images as needed, send it to admin@iscfs.org no later than Monday, September 16.



OCTOBER 2024

21ST ISCFS CONGRESS

"Mark your calendar and stay tuned as more information will follow in the coming months."

SHANGHAI VISIT 2024

On July 24 - 28, the ISCFS management team traveled to Shanghai to meet with the President, Dr. David Mu, and his team at the 2025 Congress venues.

Arrival and entry at Shanghai Pudong International Airport went smoothly. Since the beginning of the year, travelers from many countries no longer require a visa, so the process at the airport was simple and absolutely seamless.

Shanghai is a stunning city, combining both historic and modern elements with rich cultural diversity. This vibrant metropolis offers numerous opportunities for events at first-class hotels.

The site inspection trip to Shanghai was a complete success. We are excited about all that Shanghai offers - a great place to bring partners and family - and are looking forward to organizing the congress together with Dr. Mu and his team.

Mark your calendar and stay tuned as more information will follow in the coming months.

**SEE YOU IN SHANGHAI:
OCTOBER 27-31, 2025**



WINDOW INTO HISTORY

CLOVERLEAF DEFORMITY - THE FIRST ILLUSTRATION IN MEDICAL LITERATURE

In 1849, the Dutch anatomist Willem Vrolik (**Figure 1**) published a superb atlas on congenital malformations in men and animals which contains illustrations of numerous craniofacial deformities. Among them is a case of cloverleaf deformity or triphyllocephaly, most likely the first example in medical literature of this rare malformation.

Tabulae ad Illustrandam Embryogenesis Hominis et Mammalium

(Plates to illustrate Embryogenesis of Men and Animals) (1) (**Figure 2**), is a reference point for congenital malformations in men and animals. Bilingually written in Latin and Dutch, the work contains 100 full page plates illustrating numerous rare anomalies, like bladder extrophy, cleft lip and palate, spina bifida, hydrocephalus, acrania, posterior and anterior meningoencephalocèles, cyclopia, lateral facial cleft, hypospadias and hermaphroditism. The *Tabulae ad Illustrandam*

Embryogenesis, one of the most spectacular atlases on congenital deformities ever published, was awarded the Montyon prize by the French Academy of Sciences in 1850.

THE ILLUSTRATION OF CLOVERLEAF MALFORMATION

The atlas includes what we consider the first illustration of clover-leaf malformation (Triphyllocephaly). The front view of the male creature shows a trilobular cranial deformity, resulting from the premature synostosis of the lamboidal and coronal sutures. The dramatic superior expansion of the head, regarded a hydrocephalus internus (internal hydrocephalus) by Vrolik, is accompanied by two lateral, symmetric bulgings in the temporal region, with low implantation of the auricles and downward slanting of the palpebral fissure (**Figure 3**). On examining the skull, one notices that the frontal bone is vertically directed, whereas parietal bones are laterally expanded. The occiput is



RICCARDO F. MAZZOLA

History Editor
ITALY

"During his career, he amassed an important collection of human anatomical specimens, both normal and pathological..."



Figure 1 - Willem Vrolik

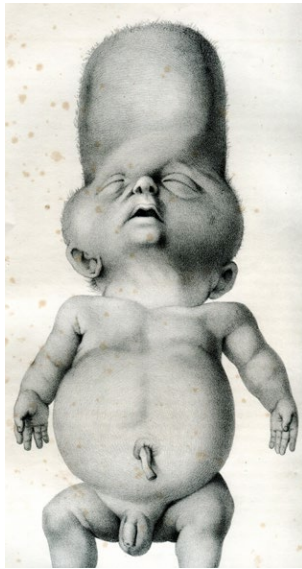

Figure 3 - Newborn with cloverleaf malformation. Front view. From: Vrolik W. *Tabulae ad Illustrandam Embryogenesis Hominis et Mammalium*, 1849

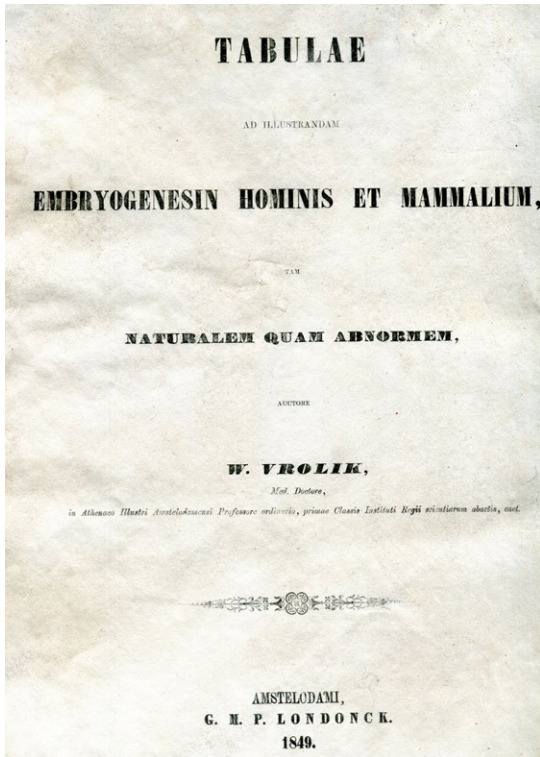


Figure 2 - Title page of *Tabulae ad Illustrandam Embryogenesis Hominis et Mammalium* (Plates to illustrate Embryogenesis of Men and Animals) by Willem Vrolik.

flat and not clearly defined from the back of the neck. The orbits are shallow, with a very short lateral orbital wall. The bridge of the nose is flat with scarcely developed nasal bones and a hypoplastic maxillary bone giving a retruded aspect to the middle third of the face (Figure 4).

Willem Vrolik (1801-1863) was the son of the anatomist Gerardus Vrolik (1775-1859). He was born in Amsterdam, studied medicine at Utrecht University pursued his medical studies in Paris where he obtained his medical degree in 1823. Back in The Netherlands, he was appointed a Professor of Anatomy and Physiology at Gröningen University in 1829, and two years later became a Professor of Anatomy and Physiology at the *Atheneum Illustre* (University of Amsterdam), where he remained until his death.

His main interest was the study and pathogenesis of congenital anomalies, skeletal disorders and comparative anatomy. During his career, he amassed an important collection of human anatomical specimens, both normal and pathological, with numerous examples of rare congenital malformations, initiated by his father Gerardus, now preserved in the Vrolik Museum in Amsterdam, specifically dedicated to the human body.

Willem Vrolik published numerous scientific works on human congenital anomalies, embryology and comparative anatomy.

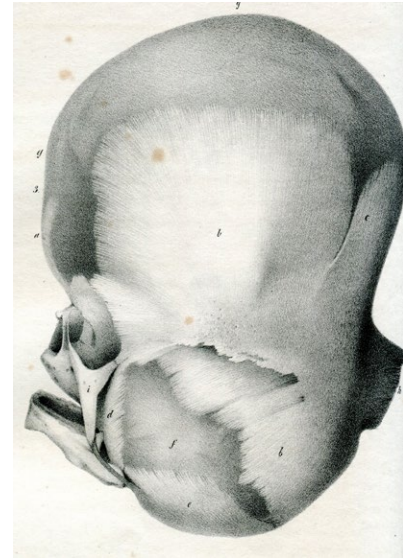


Figure 4 - Profile view. From: Vrolik W. *Tabulae ad illustrandam Embryogenesis Hominis et Mammalium*, 1849

REFERENCE

1. Vrolik W. *Tabulae ad Illustrandam Embryogenesis Hominis et Mammalium* (Plates to illustrate Embryogenesis of Men and Animals). Amsterdam, G.M.P. Londock, 1849

NEUROSURGERY CORNER

"Standard knowledge tells us that in a patient without craniosynostosis, raised intracranial pressure is the primary finding, that then causes an increase in the size of the head as compensation, in an effort to normalise the Intracranial pressure."



JAY JAYAMOHAN
Neurosurgery Editor
UNITED KINGDOM

Something I've been thinking about through most of my career, and perhaps more than usual over the last few years, has been the question of intracranial pressure. What is a normal intracranial pressure? How big is the shoulder of "high normal" before we can state that it is abnormally high? And what is the correlation between clinical findings numbers on a screen?

Standard knowledge tells us that in a patient without craniosynostosis, raised intracranial pressure is the primary finding, that then causes an increase in the size of the head as compensation, in an effort to normalise the Intracranial pressure. However, in a patient with craniosynostosis, the limitation in head growth imposed by the premature fusion of one or more sutures does not allow intracranial volume to increase per the increase in cerebral volume or CSF volume depending on the condition. It has been a long-standing opinion in our unit that a patient who does not show the shape change associated with any particular suture fusion is at increased risk of developing

raised intracranial pressure. So, for example the child with sagittal craniosynostosis, but who does not develop the classical scaphocephalic head shape, does not have the benefit of the increased growth at the other sutures to try to maintain volume at the expense of head shape.

We now have a collection of patients who presented initially with a referral to the neurosurgical department with "Chiari malformation," but who actually had tonsillar herniation secondary to raised intracranial pressure. Investigations revealed these children to have a sagittal synostosis, but with a small normal head shape. Those patients who clearly have papilledema associated with symptoms of raised intracranial pressure presenting in such a way will sometimes go on to have a calvarial expansion occasionally interspersed by a trial of acetazolamide while being investigated for benign intracranial hypertension.

Some of these children have intracranial pressure monitoring and these results are often used to help decision-making. Is it reasonable for us to use

an assessment of numbers and traces on a screen to decide what is abnormal and abnormal when it comes to intracranial pressure? In Oxford, we have spent many years looking at this with a large number of patients. The rudimentary opinion would be summarised as more than three B waves in a 24-hour period or a sustained baseline of more than 15 millimetres of mercury would count as raised pressure.

But when we review the charts, it is much more than these numbers. The peaks and troughs on a pressure trace can help assess compliance. Those children with higher levels of amplitude are considered to have lower compliance within the intra cranial space and are therefore edging towards developing true raised intracranial pressure. Depending on the history provided, I would sometimes opine that even without 3 B waves, a child with a high baseline and regular high amplitude has raised pressure sufficient to discuss surgery with the family.

Most people would be comfortable agreeing that those patients with true A wave plateaus have raised intracranial pressure, especially since these patients invariably have a significant number of symptoms, supported by the findings on examination and investigation, but the B wave conundrum

continues to be an issue. In his seminal 1960 paper, Lundberg describes pressures of between 20 and 50 mmHg that have a wave frequency of 0.5 to 2 waves per minute. Interestingly, this was initially thought to be probably due to variations in blood pressure within the cerebrum, and to periodic breathing. Over time, the frequency has been widened to between 1/3 and 3 waves per minute, and even suggested to be up to 4 waves per minute.

This widening of the definitions then inevitably led to a sub-classification of B waves. While not universally accepted, most of these definitions attempt to separate persistent or plateau B waves from those with episodic B waves or those with continuous regular B waves.

What does all this mean then for our craniofacial practice? Well, it means that while we will need to continue to investigate some patients for raised intracranial pressure, the results of such investigations must not be taken at face value when summarised in a discharge summary. I would encourage colleagues to have a group review of the tracings on ward rounds or at a multidisciplinary team meeting, discuss what this means in conjunction with the presentation and clinical findings, and use them to come back with a holistic analysis of the patient.

When viewed in isolation, we risk most likely over diagnosing raised intracranial pressure, and most certainly erroneously interpreting the pressure results either way. This may lead to patients either not having surgery that they need or having unnecessary procedures.

Please do email me at admin@iscfs.org with any thoughts or comments on this or any topic that tickles your neurosurgical fancy. Otherwise, these will continue to be the ramblings of a slightly overweight man in Oxford. Thanks!

REFERENCE

1. Lundberg N. Continuous recording and control of ventricular fluid pressure in neurosurgical practice. *Acta Psychiatrica Scandinavica Supplementum*. 1960;36:1-193

ORTHODONTICS UPDATE

"Orthodontists play a crucial role in managing the dental and skeletal discrepancies associated with this condition."



MARIANA SABÁS
ARGENTINA



MARÍA ANA MUÑOZ
ARGENTINA

ORTHODONTIC TREATMENT IN HEMIFACIAL MICROSOMIA

Hemifacial microsomia (HFM) is the second most common craniofacial anomaly, following cleft lip and palate, affecting one in 3,000 to 5,600 newborns. It is always unilateral, as indicated by the name, more prevalent on the right side (70-90% of cases), and occurs more frequently in males than females. HFM was first described by the ophthalmologist Maurice Gondenhar in 1952. HFM results from abnormal development of the first and second branchial arches during embryonic growth, affecting structures such as the mandible, maxilla, articular cavity, orbit, auditory canal, ear, and soft tissues and muscles innervated by the trigeminal and facial nerves. The etiopathogenesis is multifactorial, involving genetic and environmental factors. This condition exhibits variable phenotypic expressions, with a spectrum of severity

ranging from mild asymmetry to significant facial deformities, depending on the number of structures involved and the penetrance of the syndrome.

Pruzansky (1969) and Kaban (1998) classified HFM based on the severity of mandibular deformity:

- **Grade I:** TMJ components are present and have a normal shape, but exhibit minimal hypoplasia.
- **Grade II A:** Hypoplasia and inadequate position allow for mandibular functional movement.
- **Grade II B:** The mandibular ramus shows hypoplasia, with abnormal shape and location, causing TMJ malfunction.
- **Grade III:** The mandibular ramus, condyle, and TMJ are absent.

Facial asymmetry results from the underdevelopment of the affected side and

transverse changes in mandibular position due to reduced development of the temporomandibular joint components and mandibular ramus. Structures adjacent to bony components that exhibit vertical changes on the affected side cause maxillary, occlusal, and commissural canting. The lack of secondary development of the maxillary, zygomatic, and malar bones affects the adjacent soft tissues as well. Orthodontists play a crucial role in managing the dental and skeletal discrepancies associated with this condition.

The treatment approach for patients with HFM often involves a multidisciplinary team, including orthodontists, craniofacial plastic surgeons, oral surgeons, and otolaryngologists, among others. The literature reports different treatment modalities depending on the patient's age, severity of symptoms, and the specialists involved. Orthodontists assess dental and skeletal alignment, focusing on correcting malocclusions, improving jaw relationships, and aligning teeth to enhance both function and aesthetics.

Our treatment focuses on the following objectives:

- Increase mandibular size and associated soft tissues.
- Correct secondary deformities in the maxilla.
- Improve dental position and smile arch.
- Correct dental canting.

- Establish a functional occlusion.
- Improve facial and dental aesthetics.

Early intervention is essential in managing hemifacial microsomia to guide facial growth and development. Orthodontic treatments, such as dentofacial orthopedics, braces, expanders, and aligners, combined with surgical procedures (distraction osteogenesis and orthognathic surgery), are utilized to optimize facial symmetry and function. During the first phase in mixed dentition, orthodontists assess dental eruption and correct crowding and transverse arch problems. It is often necessary to assist the surgeon with mandibular distraction using appliances and elastics during the distraction process. The goal is not only to improve the patient's appearance, but also to restore proper occlusion and dental function, which are critical for overall oral health. Orthodontic treatment plans are tailored to the individual patient based on the severity of their condition and specific anatomical abnormalities. With the evolution of 3D computed tomography imaging, the visualization of skeletal complexities in different perspectives has greatly enhanced surgical planning, especially for asymmetrical patients.

Beyond the physical aspects, orthodontic treatment for

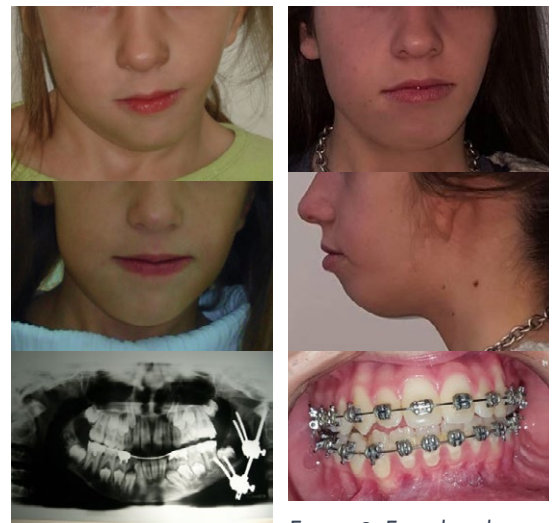

Figure 1. Pre- and post-osteogenesis distraction in mixed dentition.

Figure 2. Facial and dental photographs of completed presurgical orthodontics.

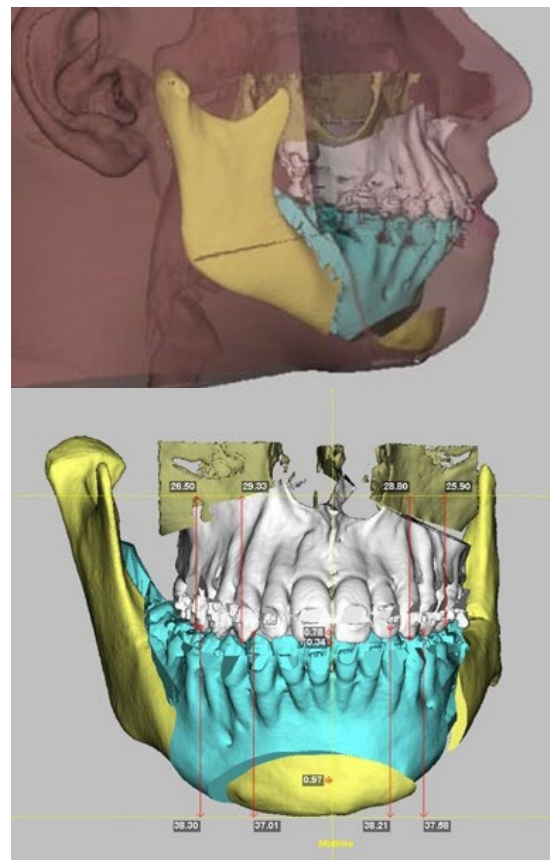


Figure 3. Virtual 3D orthognathic surgery planning.

"Beyond the physical aspects, orthodontic treatment for hemifacial microsomia also addresses the psychological impact of facial asymmetry."

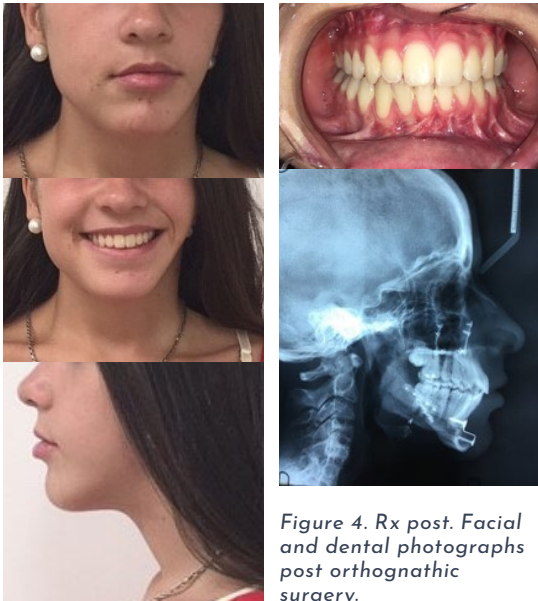


Figure 4. Rx post. Facial and dental photographs post orthognathic surgery.

hemifacial microsomia also addresses the psychological impact of facial asymmetry. Patients may experience social challenges due to their appearance, and orthodontic intervention can significantly improve self-esteem and quality of life.

Surgical interventions are corrective and may include distraction osteogenesis (DO) to elongate the mandibular skeleton on the affected side and orthognathic surgery to correct the size and position of compromised structures. Additionally, grafts, articular prostheses, and plastic and reconstructive surgery may be utilized as necessary.

We present one case study: The patient is affected by HFM type IIB. The surgeon was Dr. Emmanuela Nadal.

In conclusion, orthodontics plays a pivotal role in the comprehensive management of hemifacial microsomia. Through early diagnosis, coordinated treatment planning, and advanced

orthodontic techniques, patients can achieve improved facial aesthetics, function, and psychosocial well-being. Continued research and collaboration among dental and medical specialists are essential for advancing treatment strategies and enhancing outcomes for individuals affected by this complex condition.

This article provides an overview of the relationship between orthodontics and hemifacial microsomia, emphasizing the importance of orthodontic intervention in managing both the functional and aesthetic aspects of the condition.

RESIDENTS & FELLOWS CORNER

"One of the most remarkable aspects of my time in Seattle was learning about the latest technological advancements in craniofacial surgery..."



**RODRIGO ANDRÉS
PENAGOS-LUNA**
COLOMBIA

THE ISCFs AS A TRANSFORMATIVE EXPERIENCE

As a first-year plastic surgery resident at the Universidad del Valle in Cali, Colombia, I had the remarkable chance to attend the ISCFs congress in Seattle in 2023. This event was a major milestone in my professional journey and provided a deep dive into craniofacial surgery, a field that greatly captivates me.

I went to Seattle with two professors and a chief resident, all of whom have been instrumental in my training. Both academically and personally, I owe them a great deal, since they planted the basis for the surgeon I wish to become. During the congress, we had the privilege of sharing our experiences and research, bringing personal gratification and highlighting the dedication and hard work of our team.

One of the most remarkable aspects of my time in Seattle was learning about the latest technological advancements in

craniofacial surgery, such as virtual surgical planning tools and augmented reality applications. As a first-year resident, my familiarity with these technologies was limited, and discovering them was enlightening. Although these tools are not readily accessible in Colombia, gaining this knowledge has broadened my perspective and increased my enthusiasm for my role in craniofacial surgery.

I was also fortunate to meet leading figures in craniofacial surgery, particularly Dr. Jesse Taylor from the Children's Hospital of Philadelphia. His groundbreaking research, exceptional technical skills, eagerness to share his knowledge, and, most importantly his humility, made a lasting impression on me. I am especially grateful to Dr. Taylor for visiting Cali, Colombia in May 2024 to share his expertise. On behalf of my school, peers, teachers, and most importantly our patients, we thank you. I hope this mentorship

"We are thrilled to invite you to contribute to the Young Surgeon's Corner of the ISCFS Newsletter!"

continues to grow, fostering joint progress that benefits all of our patients.

Being named a member of the ISCFS at the last congress was an incredible honor, especially as the only Latin American resident to receive this recognition. As a new member, I have had the chance to learn and grow through the society's webinars and quarterly newsletter. These practical, case-based resources have greatly enhanced my training and reinforced my passion for this field.

My involvement with the ISCFS has been a transformative experience, solidifying my

commitment to craniofacial surgery. I aim to continue developing and contributing to this specialty with the same dedication and passion inspired by my mentors and colleagues.

I must express my gratitude to Dr. Diego Caycedo and Dr. Marcela Cabal, who introduced me to this field and showed me its potential impact on our patients' lives. Their guidance and support have been crucial in my professional development.

I look forward to continuing this journey and learning more from everyone at the next congress in Shanghai in 2025. See you there!

INVITATION TO CONTRIBUTE TO THE **YOUNG SURGEON'S CORNER** OF THE ISCFS NEWSLETTER

Dear Resident and Fellow members of the ISCFS,

We are thrilled to invite you to contribute to the Young Surgeon's Corner of the ISCFS Newsletter! This platform is designed to highlight the perspectives, insights, and achievements of our dynamic and talented members in training. Our goal is to foster a collaborative and supportive community where young surgeons can learn from each other and gain recognition for their contributions. Whether you have a compelling case study, a breakthrough in research, or reflections on your training journey, we encourage you to share your story with us.

To contribute, please contact me at ben.massenburg@gmail.com

Join us in making the Young Surgeon's Corner a rich and compelling part of the ISCFS Newsletter!

BEN MASSENBERG, MD
Chair, Residents and Fellows Committee

ISCFS WELCOMES NEW MEMBERS

A recent By-Laws change now allows voting to admit new members to be carried out electronically, twice each year. Our first such ballot was sent to all current Active Members last month. The next one will be sent in December.

This action by the Council now allows ALL Active members to participate, no longer limiting the vote to those in attendance at the biennial business meeting during an ISCFS Congress.

I am delighted to welcome the following colleagues as our newest members:

ACTIVE MEMBERS

Prof. Dr. S. M. Balaji - Chennai, INDIA
Cranio-Maxillofacial Surgery

Olivia Nelson, MD - Philadelphia, PA, UNITED STATES
Anesthesiology

Bin Yang, MD, PhD - Beijing, CHINA
Plastic Surgery

ASSOCIATE MEMBERS

HyeRan Choo, DDS, DMD, MS - Palo Alto, CA, UNITED STATES
Orthodontics

Demetrius Coombs, MD - Dallas, TX, UNITED STATES
Plastic Surgery

RESIDENT MEMBER

Shelby Nathan, MD - Chicago, IL, UNITED STATES
Plastic Surgery

I encourage you to promote membership to your colleagues so they can join us in December. The process is not difficult with on-line applications available at:


<https://iscfs.org/membership/>



JESSE TAYLOR
ISCFS Secretary-Treasurer &
Membership Chair
UNITED STATES



BECOME AN ISCFS MEMBER



We welcome membership applications in Active, Associate, Corresponding, Orthodontic, Research, and Resident/Registrar/Fellow categories and have created a simple on-line process. Current member specialties include plastic, craniofacial, oral and maxillofacial surgeons, neurosurgeons, orthodontists, otorhinolaryngologists, dentists, and those involved in related research.

There is a \$75 application fee and annual fees are \$150 for Active/Associate members and \$50 for Resident/Registrar/Fellow members. Our website includes information about qualifications for membership and frequently asked questions at this link: <https://iscfs.org/membership/>

MEMBERSHIP BENEFITS

- Global Visibility
- International Recognition
- Reasonable yearly membership fees
- Reduced congress registration fee at the biennial international ISCFS Congress
- Professional networking

JOIN US!

ACTIVE/ASSOCIATE

RESIDENT/REGISTRAR/
FELLOW



INTERNATIONAL
SOCIETY OF
CRANIOFACIAL
SURGERY

www.iscfs.org

EVENT CALENDAR

XVII CONGRESSO BRASILEIRO DE CIRURGIA CRÂNIO-MAXILO-FACIAL (ABCCMF)

XIV CONGRESSO BRASILEIRO DE FISSURAS LÁBIO PALATINAS E ANOMALIAS CRANIFACIAIS (ABFLP)

5TH CONGRESS LATINAMERICAN CRANIOFACIAL ASSOCIATION (LATICFA)

Location: Royal Palm Hall - Campinas/SP, Brasil

Date: August 29-31, 2024

Website: www.abccmf.org.br/congresso

EUROPEAN SOCIETY OF CRANIOFACIAL SURGERY BIENNIAL CONFERENCE (ESCFS 2024)

Location: Scandic Marina Congress Center, Helsinki, Finland

Date: September 5-7, 2024

Website: <http://www.escfs.org/>

27TH EACMFS CONGRESS

Location: Rome, Italy

Date: September 17-20, 2024

Website: www.eacmfs.org

Pre-Congress Day:

September 16, 2024

ISCFS Session: September 18, 2024 - 5pm, Room 9

THE 82ND CONGRESS OF KOREAN SOCIETY OF PLASTIC AND RECONSTRUCTIVE SURGEONS

THE 27TH KOREAN CLEFT PALATE-CRANIOFACIAL ASSOCIATION

Location: Grand Intercontinental Seoul Parnas, Seoul, Korea

Date: November 17-19, 2024

Website: www.kcpca.or.kr


SAVE THE DATE 21ST ISCFS CONGRESS

Location: Shanghai, China

Date: October 27-30, 2025

Website: www.iscfs.org

To submit a meeting to the calendar in our next issue, send the following information to admin@iscfs.org: Meeting Title, Location, Dates, Website.



ISCFS MANAGEMENT

ISCFS COUNCIL

XIONGZHENG MU, China - President

IRENE MATHIJSSSEN, The Netherlands - Vice President

JESSE TAYLOR, United States - Secretary-Treasurer

RICHARD HOPPER, United States - Immediate Past President

DOV GOLDENBERG, Brazil - Council

JAY JAYAMOHAN, United Kingdom - Council

CASSIO E. RAPOSO DO AMARAL, Brazil - Council

MARIANA SABAS, Argentina - Council

DAVINDER SINGH, United States - Council

ERIC ARNAUD, France - Parliamentarian

ISCFS SOCIETY MANAGEMENT TEAM

BARBARA BOELD, Germany - Executive Director

CATHERINE FOSS, United States - Administration

VERENA REINMUTH, Germany - Administration



**INTERNATIONAL
SOCIETY OF
CRANIOFACIAL
SURGERY**

LEGAL ADDRESS

10 Penn Tower, 3400 Spruce Street
Philadelphia, PA, 19104
United States

MAILING ADDRESS

US:

38 Rayton Road
Hanover, NH 03755 USA

EUROPE:

Reitmorstrasse 25
80538 Munich, Germany

US email: admin@iscfs.org

Europe email: office@iscfs.org

www.iscfs.org



ISCFS NEWSLETTER EDITORIAL BOARD

EDITOR

JESSE TAYLOR, United States

MANAGING EDITOR

CATHERINE FOSS, United States

GRAPHIC DESIGNER

RUDITE TAUNINA, Germany

NEUROSURGERY EDITOR

JAY JAYAMOHAN, United Kingdom

HISTORY EDITOR

RICCARDO MAZZOLA, Italy

RESIDENTS/FELLOWS REPRESENTATIVE

BEN MASSENBURG, United States

EXECUTIVE DIRECTOR

BARBARA BOELD, Germany

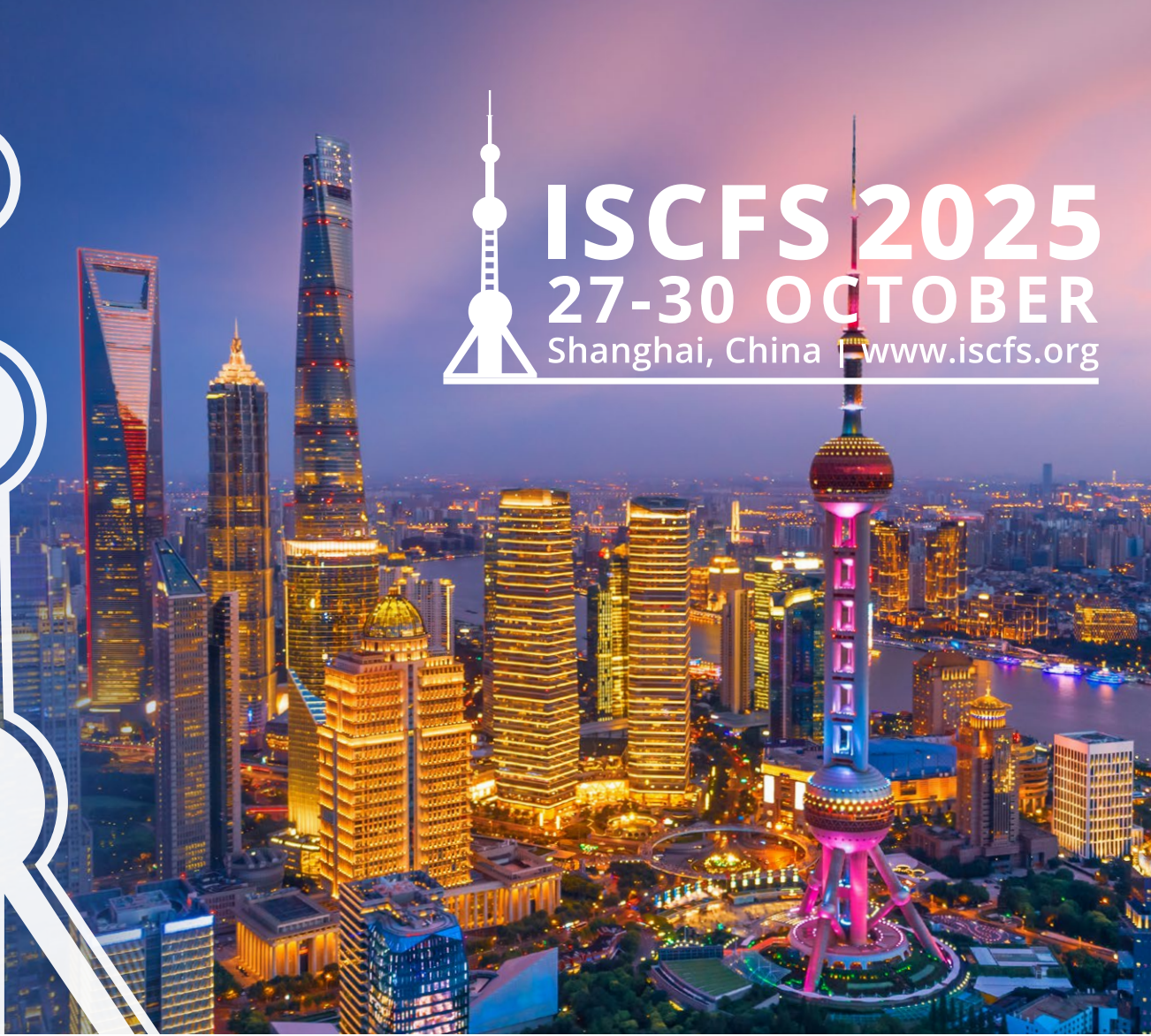DISCLAIMER: This newsletter presents information and opinions pertinent to medical professionals. It does not provide advice concerning specific diagnoses and treatments of individual cases and is not intended for use by the lay person. ISCFS is not responsible for facts, opinions, and other information presented by the authors or advertisers in this newsletter or otherwise. Readers are strongly advised to confirm that the facts, opinions, and other information comply with the latest legislation and standards of practice. ISCFS, the editors, the authors, and the publisher will not be responsible for any errors or liable for actions taken as a result of facts, opinions, and other information expressed in this newsletter or otherwise. Copyright © 2024 by the International Society of Craniofacial Surgery, Inc. All rights reserved. Contents may not be reproduced in whole or in part without written permission of ISCFS.



ISCFS 2025

27-30 OCTOBER

Shanghai, China | www.iscfs.org



**Dr. Xiongzhen Mu and Dr. Xudong Wang
invite you to Shanghai, China for the 21st Congress
of the ISCFS in **October 27-30, 2025.****



Dr. Xiongzhen Mu
2023-2025 ISCFS President



Dr. Xudong Wang
Assistant Dean, Shanghai
People's 9th Hospital

SEE YOU IN SHANGHAI!

